

# Surgical Removal of Wisdom Teeth

**Dr Hazem Al-Ahmad**  
**BDS, MSc (Lon), F.D.S. R.C.S.(Eng)**

**Associate Professor, Dental School**  
**University Of Jordan**

## ■ PREVALENCE

One study – 17% of patients over 20 year old

22% maxillary third molars

18% mandibular third molars

0.9% maxillary canines

mandibular premolars

mandibular canines

maxillary premolars

maxillary central incisors

maxillary lateral incisors

## ■ ETIOLOGY

- Differential root growth between the mesial and the distal roots.
- The relation of the bony arch length to the sum of the mesiodistal widths of the teeth in the arch
- Retarded maturation of the third molar





PORTABLE

Field Museum of Natural History

Ex: 69

blanc skeleton cat

42493

Se: 1/1

Acc: 1017

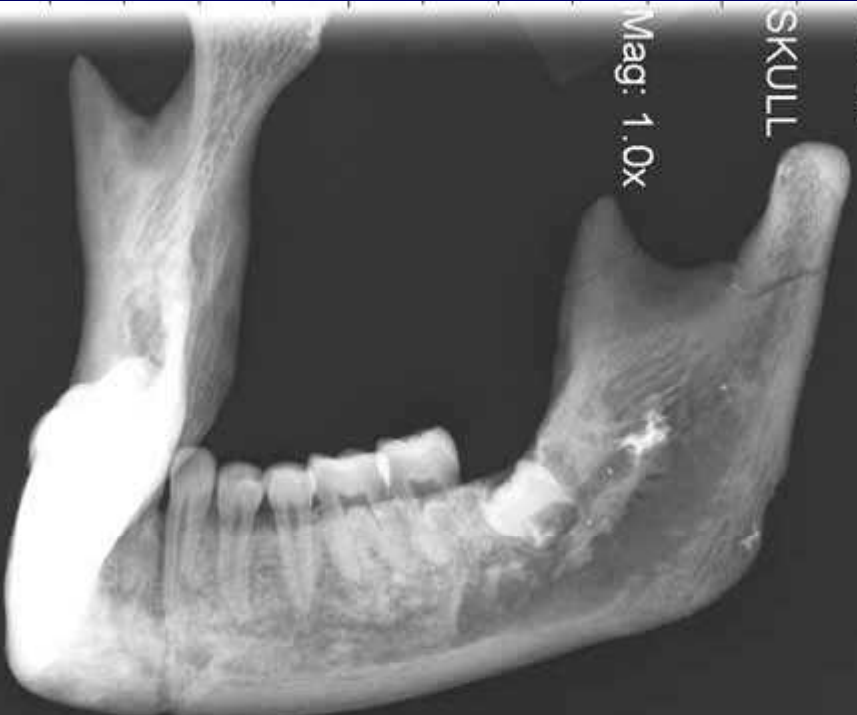Im: 1/1

2004 Dec 20

11:39:21.000000

SKULL

Mag: 1.0x



A: 4096 L: 2048

A-P

# Clinical Examination

- The patient attitude - Type of anaesthesia and/or sedation
- Age and general fitness
- The presence of facial swelling and enlarged, tender, lymph nodes.
- Surgical access - inspection of the mouth.
- The health of the 1st and 2nd molars

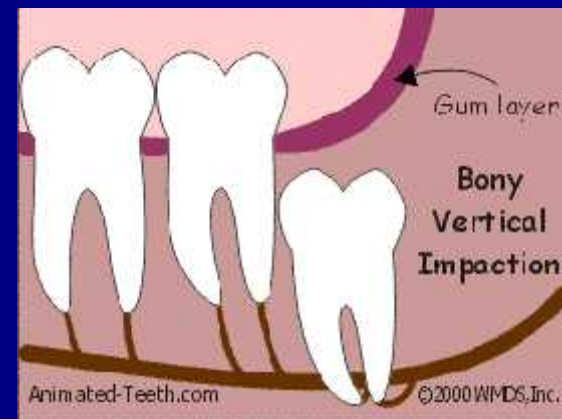
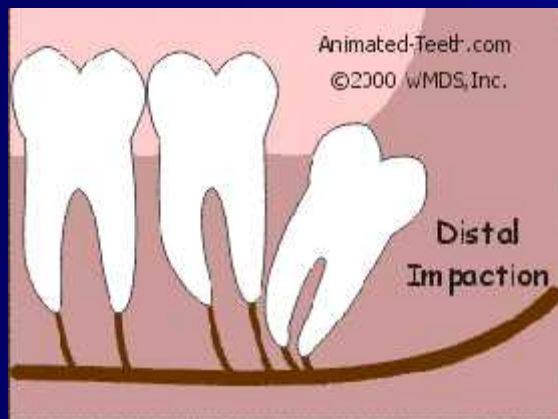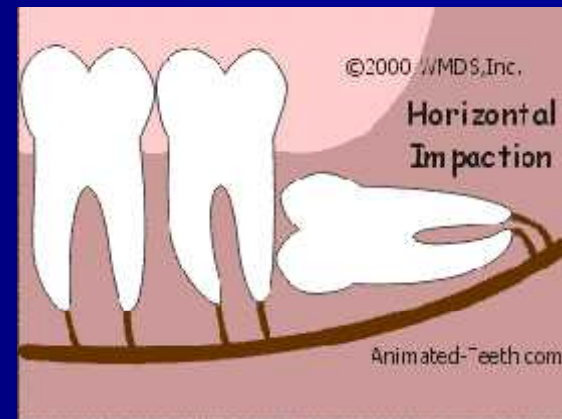
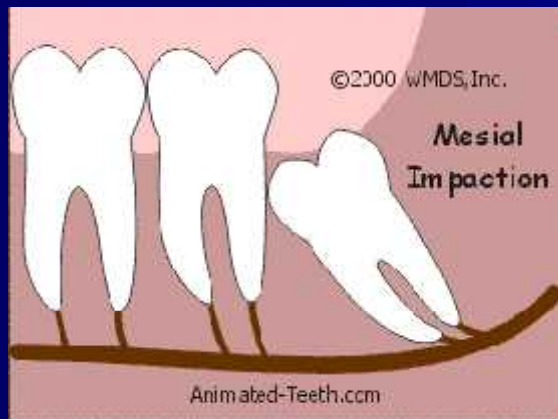# Clinical Examination

- Soft tissues over the wisdom -active pericoronitis, pus beneath the gum flap.
- The position and condition of the upper 3rd molar.
- Possible future use as a denture or bridge abutment.

# Classification systems for impacted teeth:

## Angulation:

- mesio-angular
- vertical
- disto-angular
- horizontal



# Classification systems for impacted teeth:

- Relationship to anterior border of ramus: Pell and Gregory classes 1,2 and 3:
- Class I: M-D diameter of crown is totally anterior to ant border of ramus
- Class II: one half of crown is covered by ramus
- Class III: tooth completely within the ramus

# Classification systems for impacted teeth:

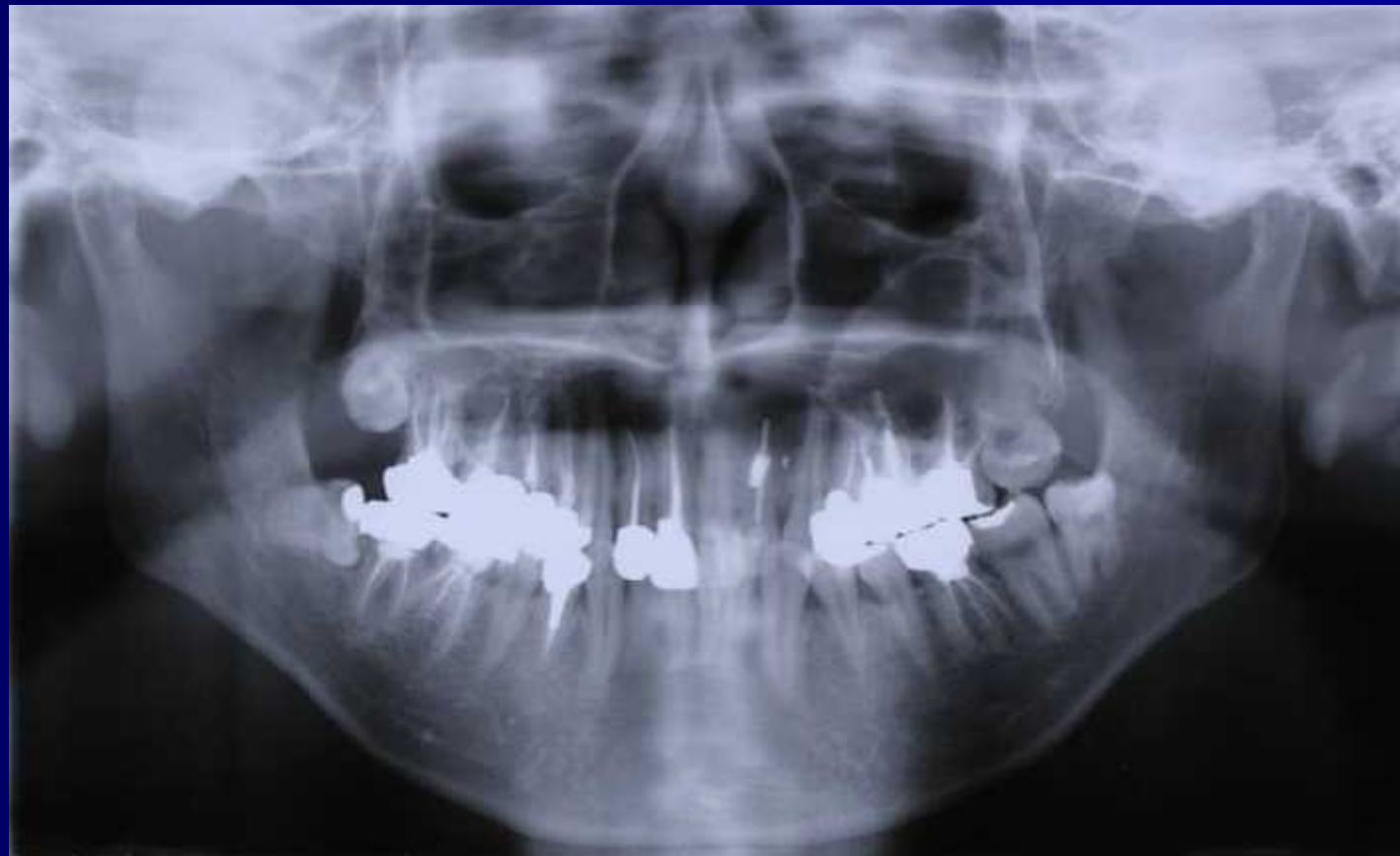- Relationship to occlusal plane: Pell and Gregory classes A , B and C:
- Class A: occlusal surface is level (or nearly) with occlusal plane of 2<sup>nd</sup> molar
- Class B: occlusal surface between occlusal plane and cervical line
- Class C: occlusal surface below cervical line

# Radiological Assessment

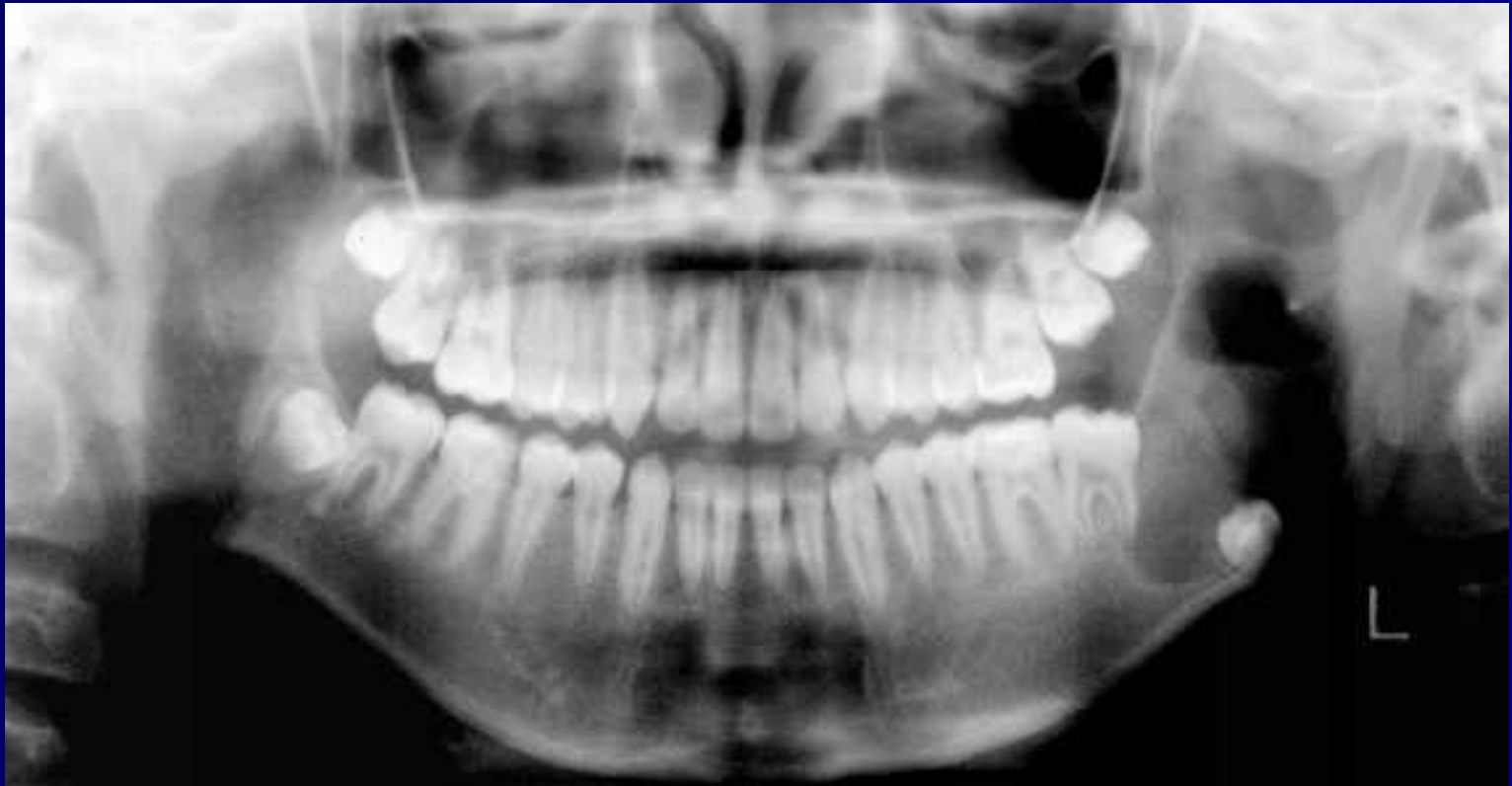1. The Orientation of the Tooth
2. The Depth of the Tooth
3. The Degree of Impaction of the Tooth
4. Root Shape
5. Bone Removal to Form a Path of Elevation

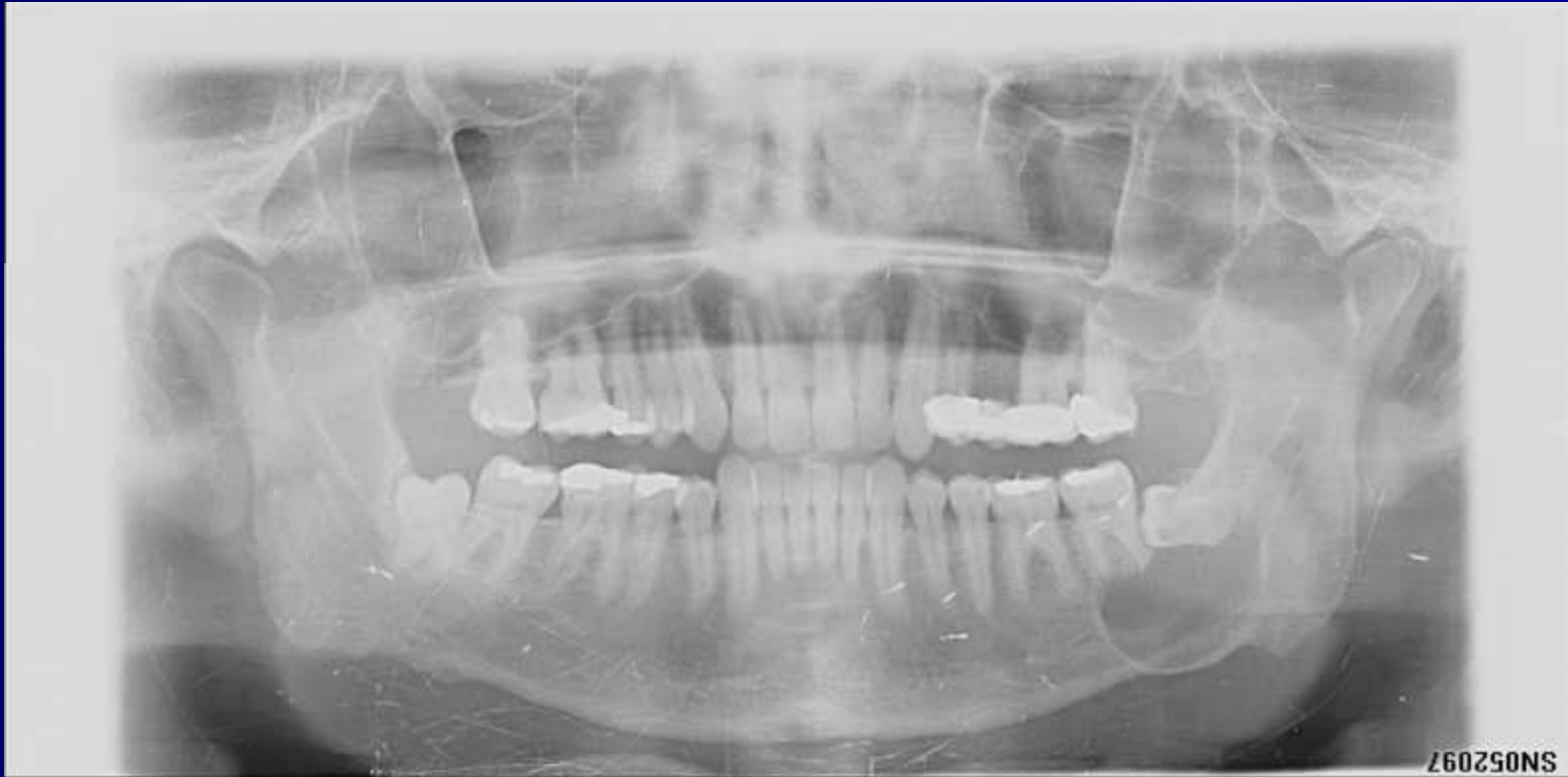6. Bone Removal to Permit Application of Elevators
7. Bone Density
8. The Relationship to the Inferior Dental Canal

# Assessment



# Assessment





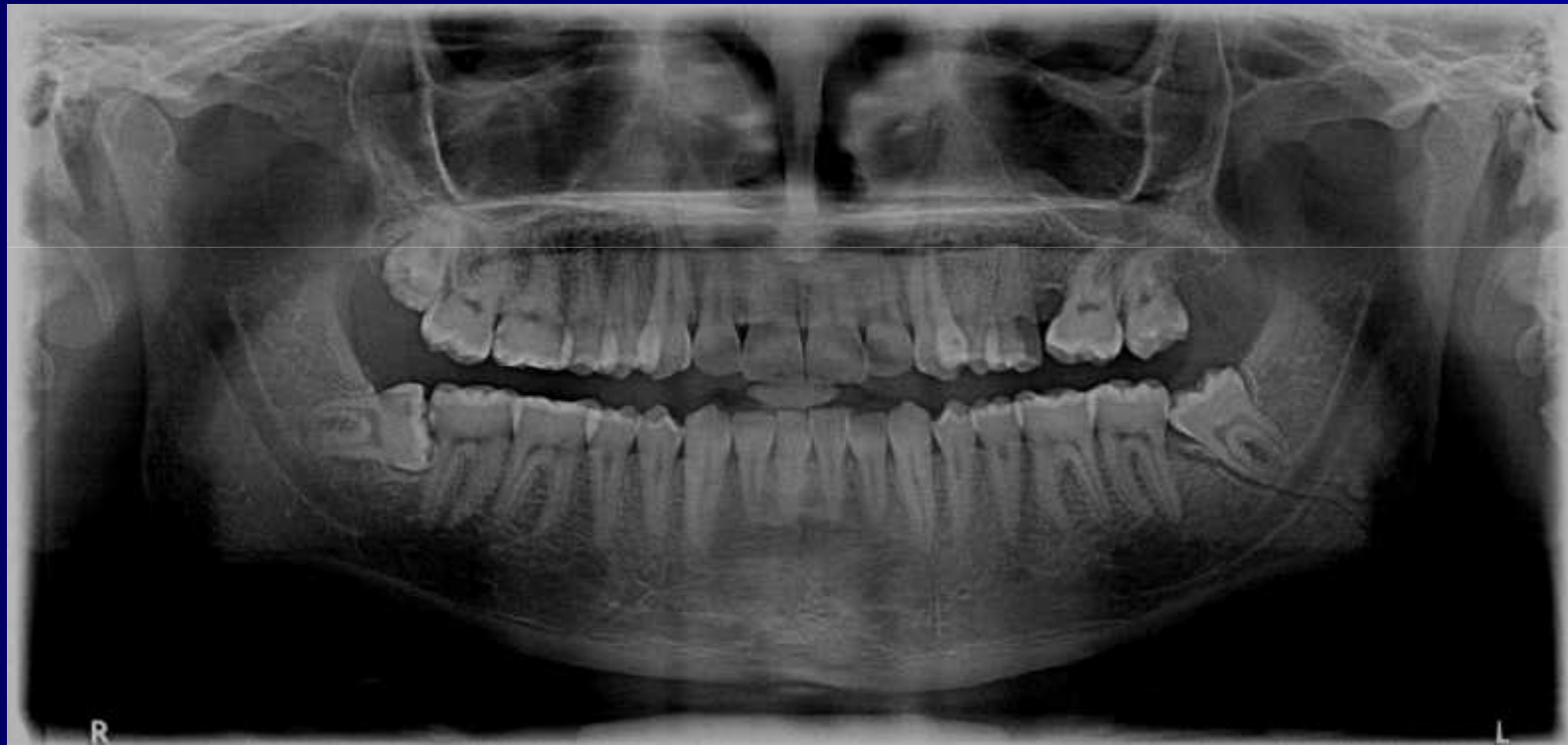SN052097

To Remove or Not to Remove

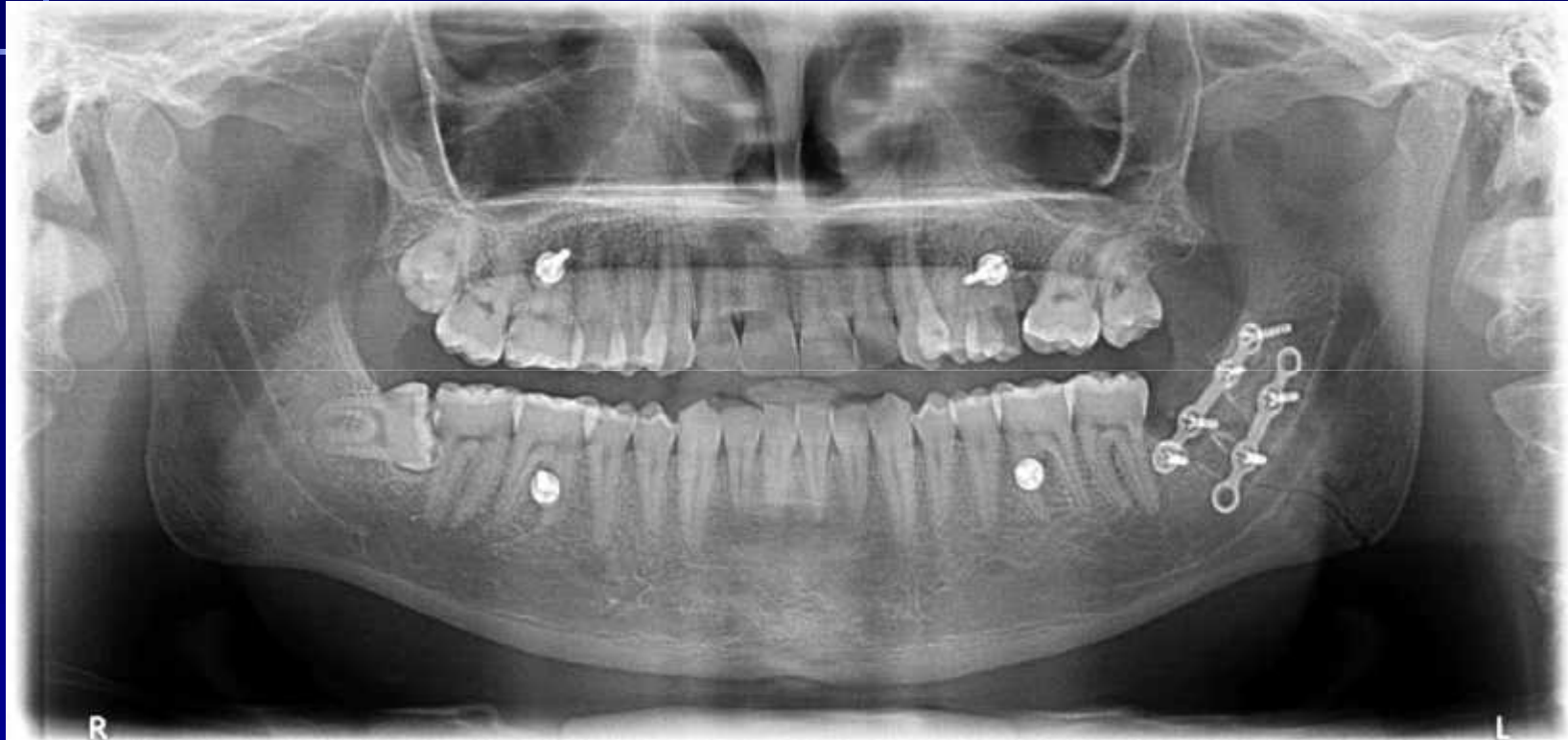- Pericoronitis
- Food packing between the crown of the impacted tooth and the second molar - caries. In later life - periodontal disease
- Suppuration around a buried tooth.
- Orthodontists - imbrication of the anterior teeth, orthodontic movement of molars distally, orthognathic surgery.

- Keratocyst
- Dentigerous cyst
- Ameloblastoma
- Prevention of jaw fracture - sports
- Resorption of alveolar bone (loss of molars with age)
- Unexplained pain

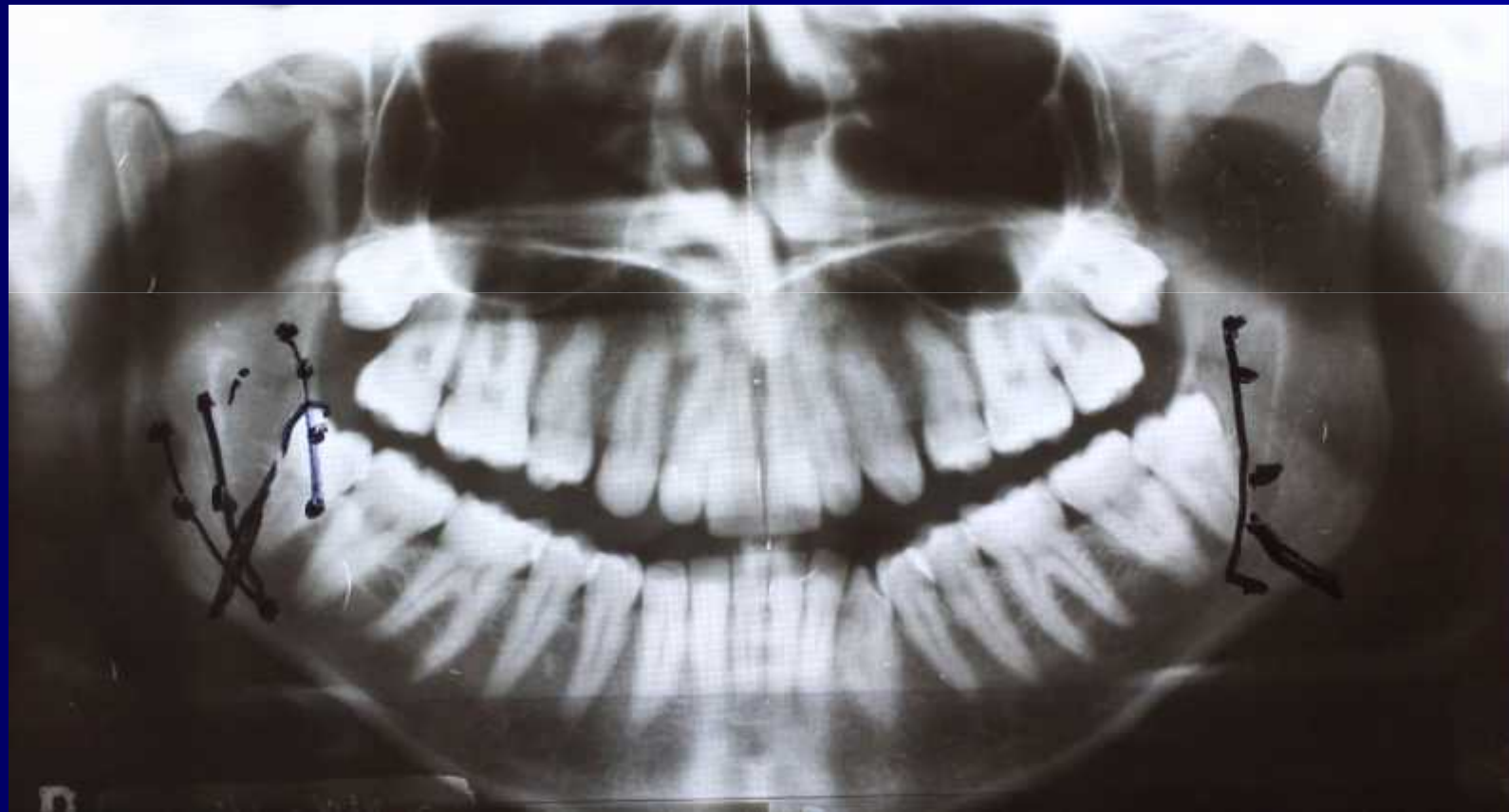
# Case 1



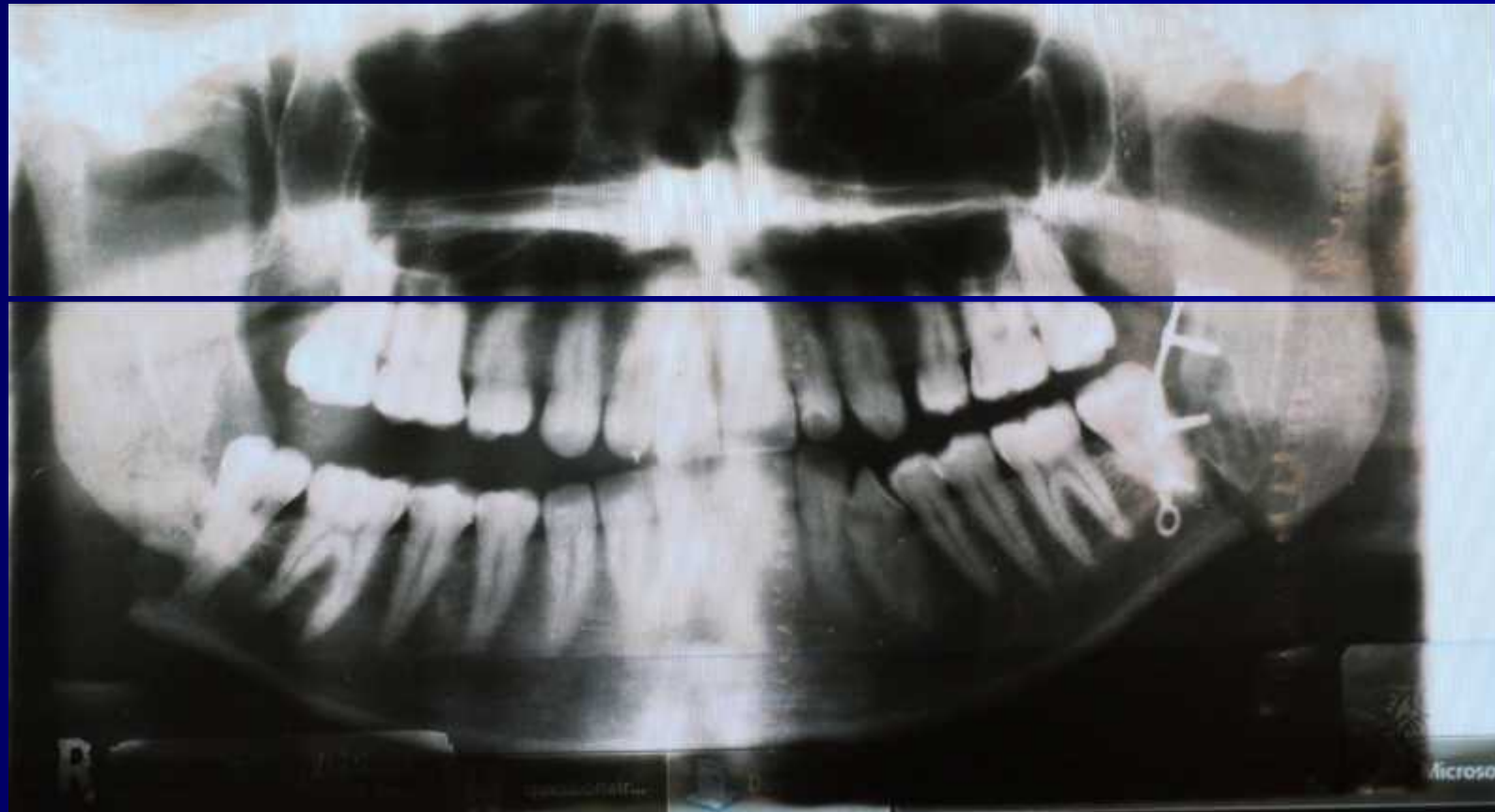
# Case 1



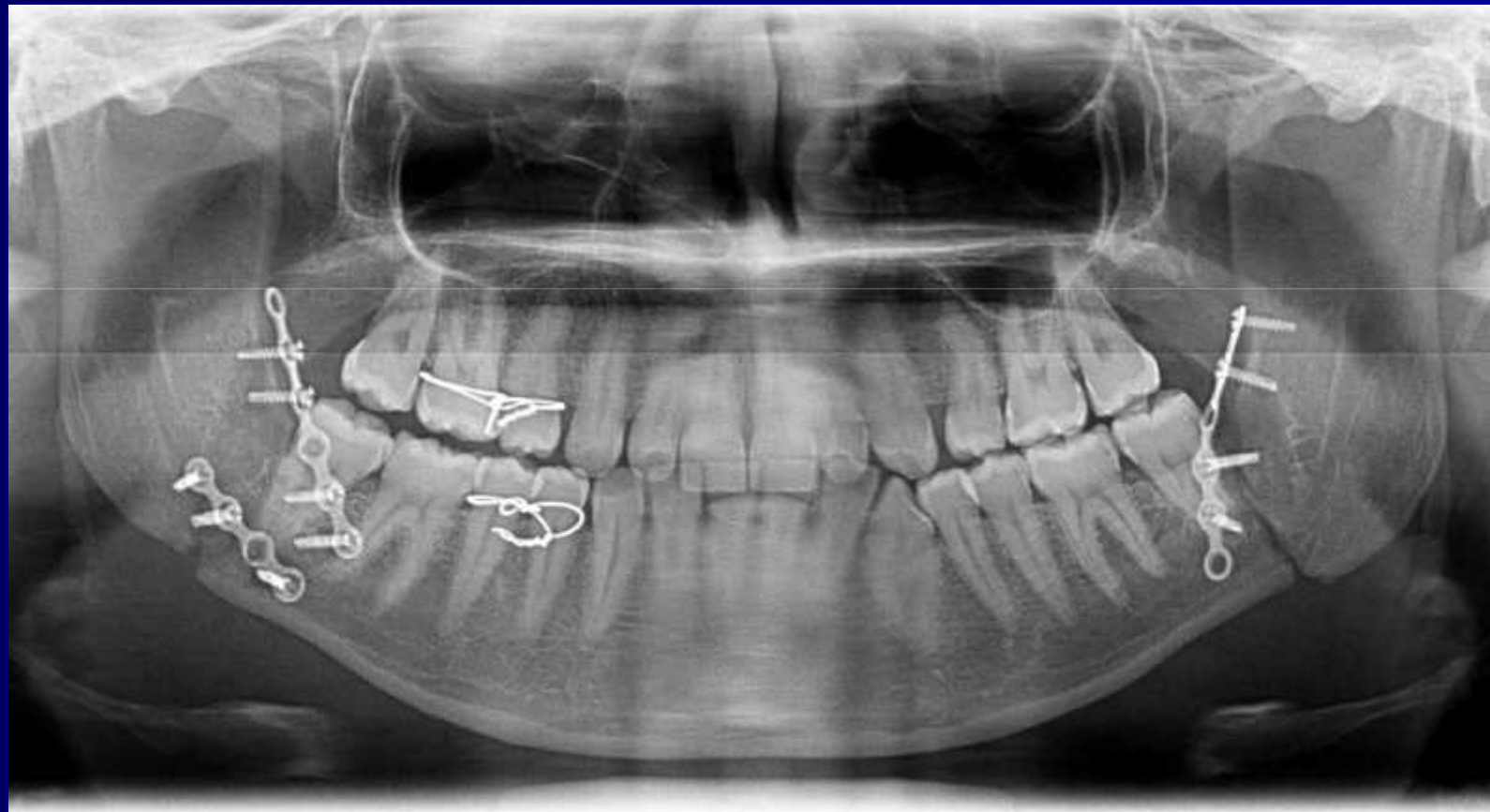
# Case 2



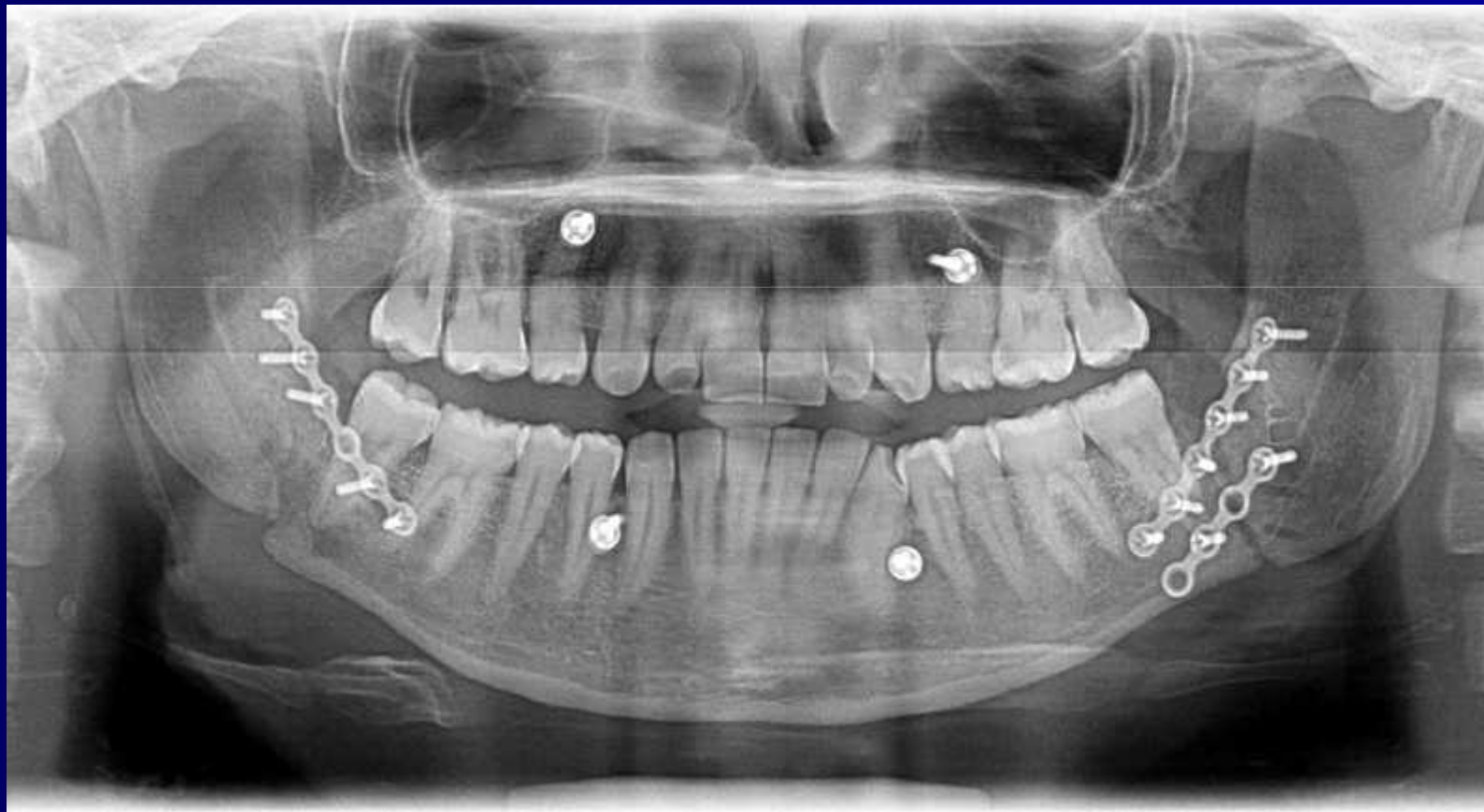# Case 2



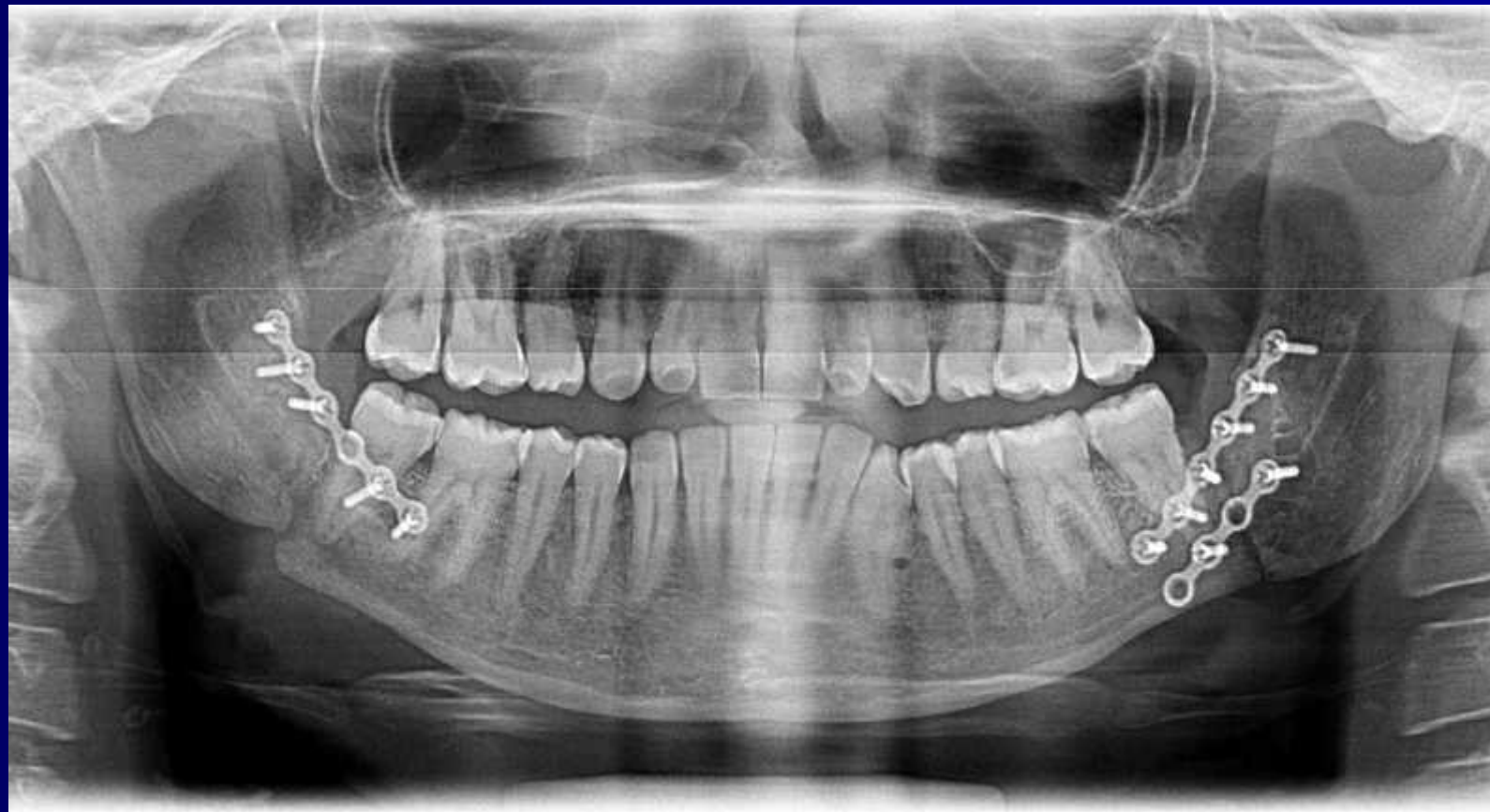# Case 2



# Case 2



# Case 2



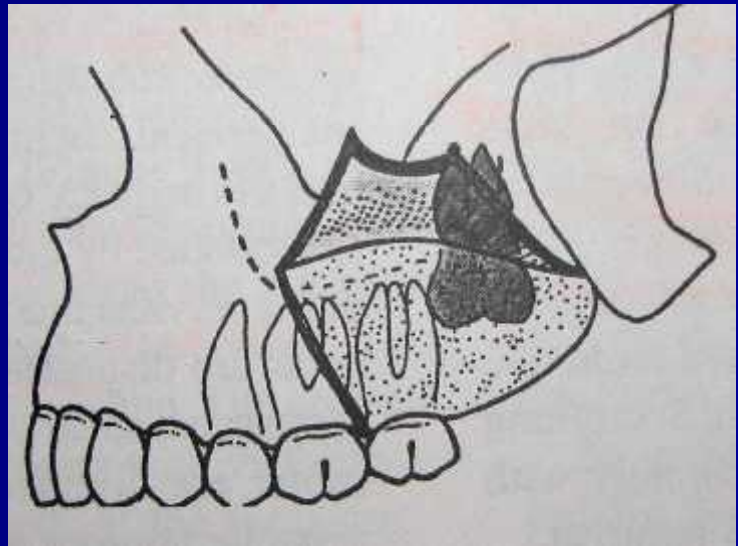
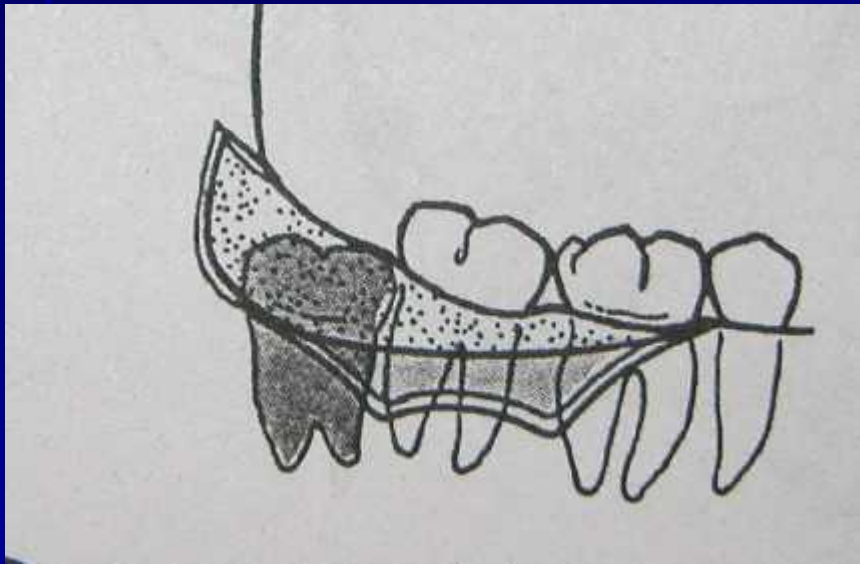
# Contraindications for removal:

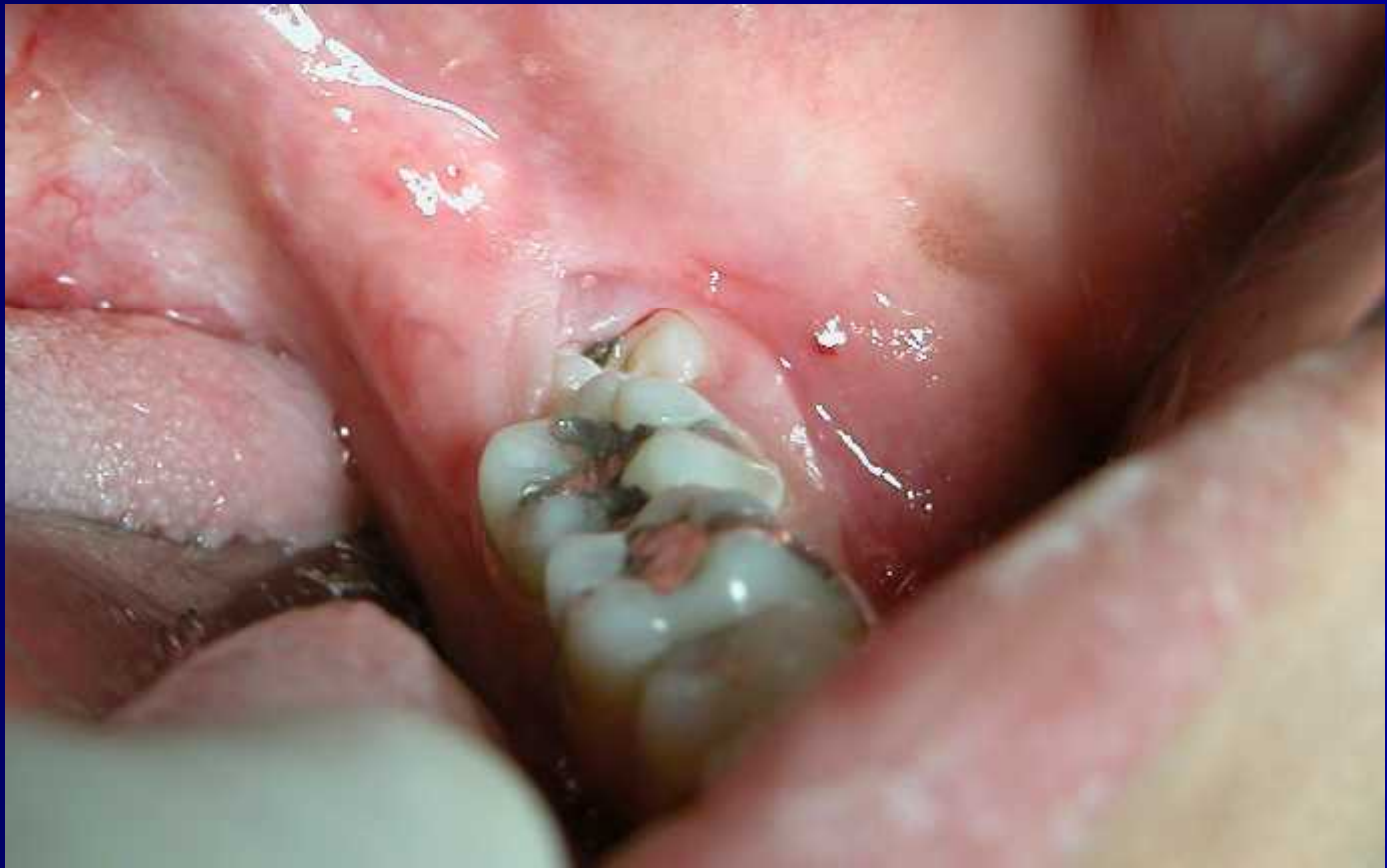- Extremes of age
- Compromised medical status
- Surgical damage to adjacent structures

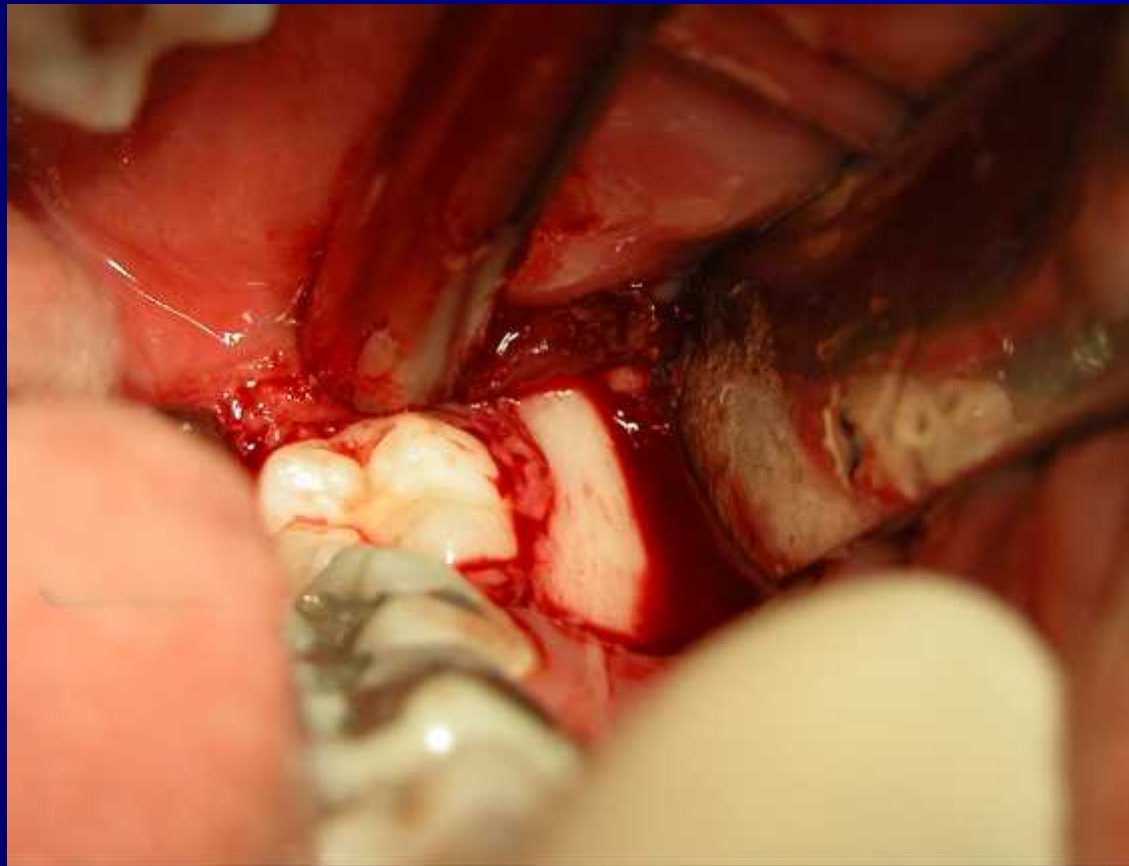
# Part II

# Basic steps

- Reflecting adequate flaps for accessibility
  - a. Envelope flap
  - b. Three-cornered flap / Triangular flap (maxillary / mandibular teeth)

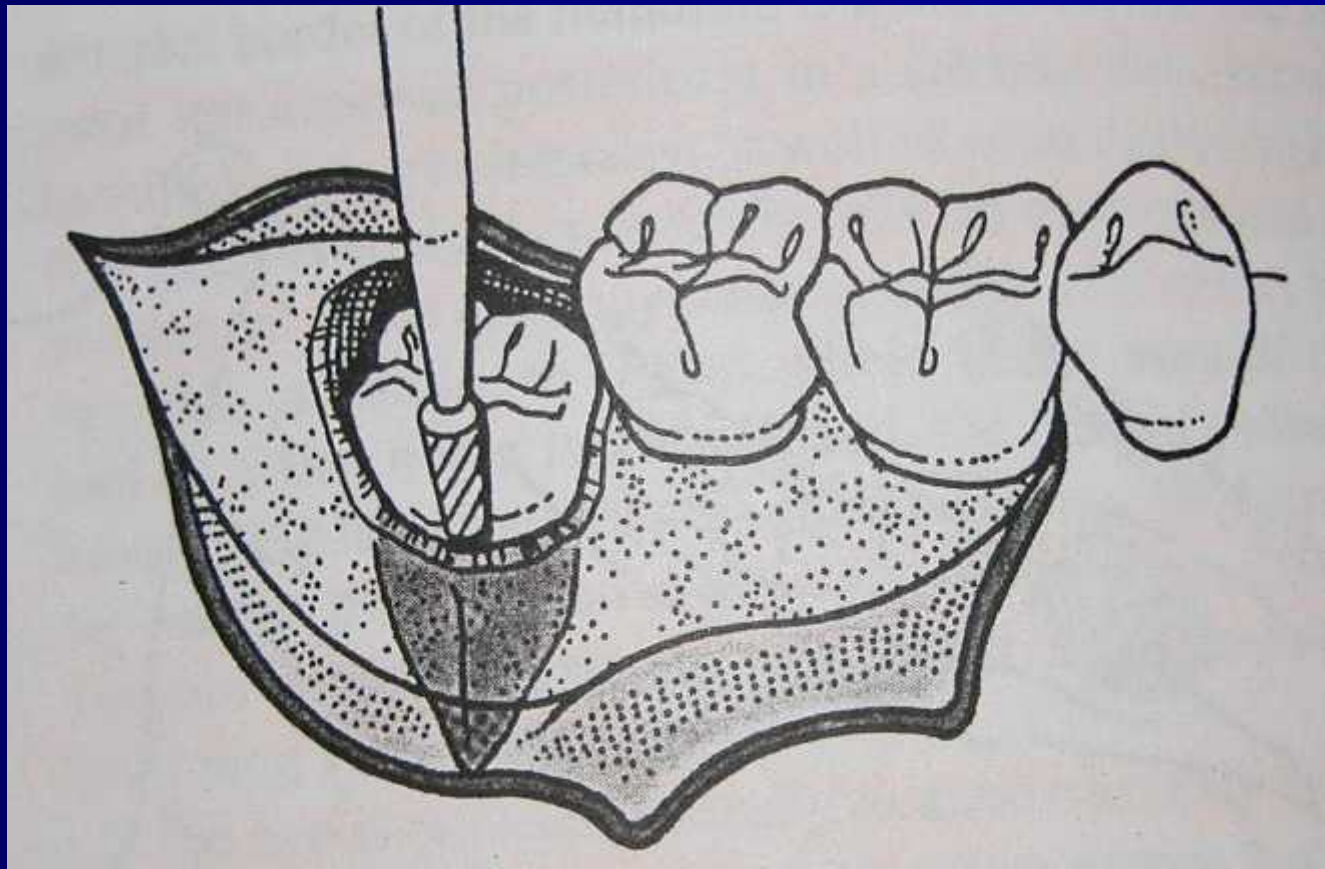






# Basic steps

- Removal of overlying bone
  - a. Chisel / drill
  - b. Lingual aspect
  - c. Maxillary/ mandibular teeth

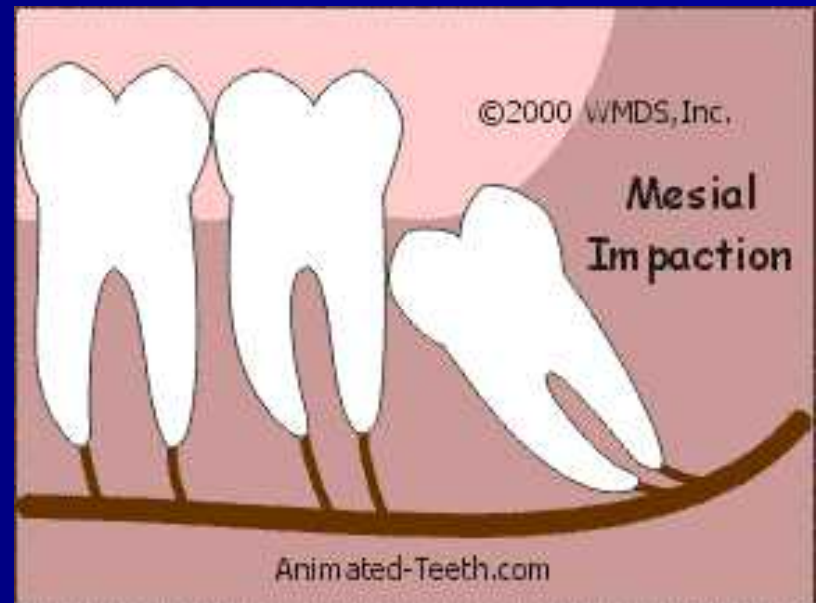

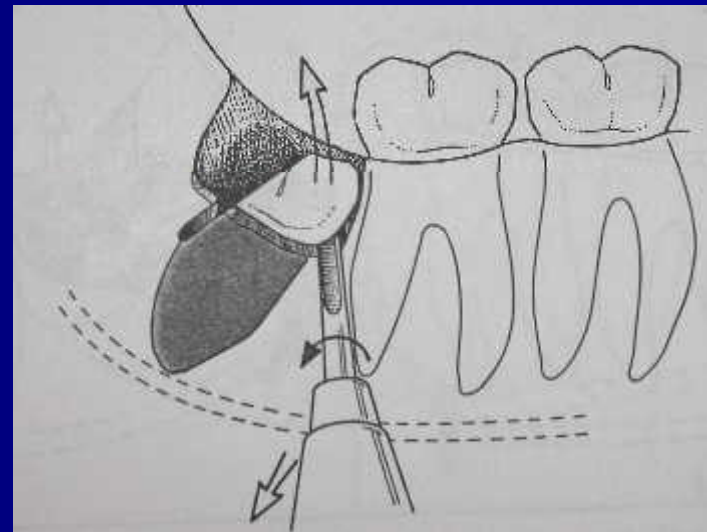
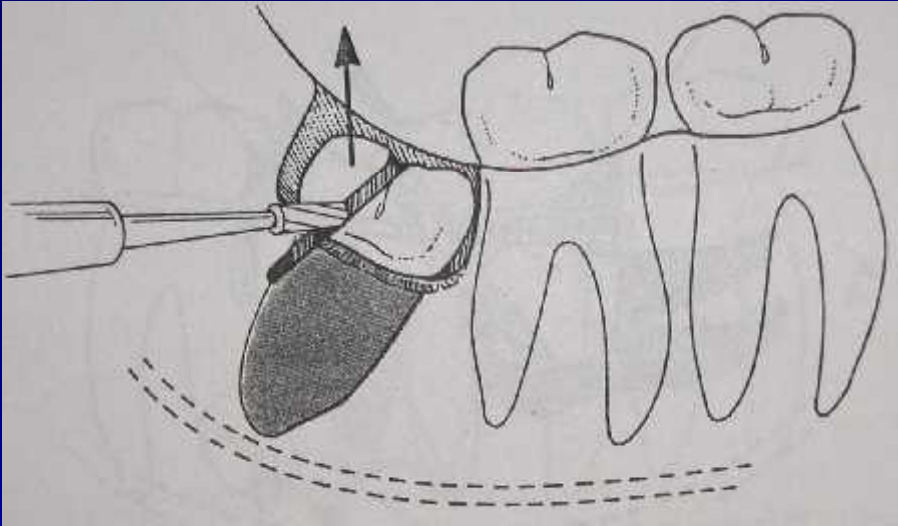
# Basic steps

- Sectioning the tooth
  - a. chisel/bur (3/4 of tooth)
  - b. Angulation of impaction

# Mesioangular

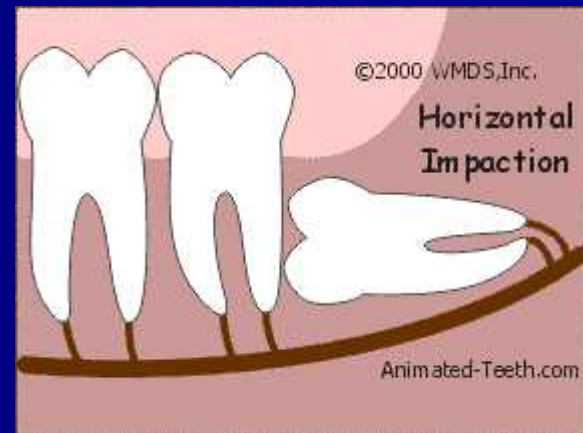- Least difficult
- Distal half of the crown is sectioned

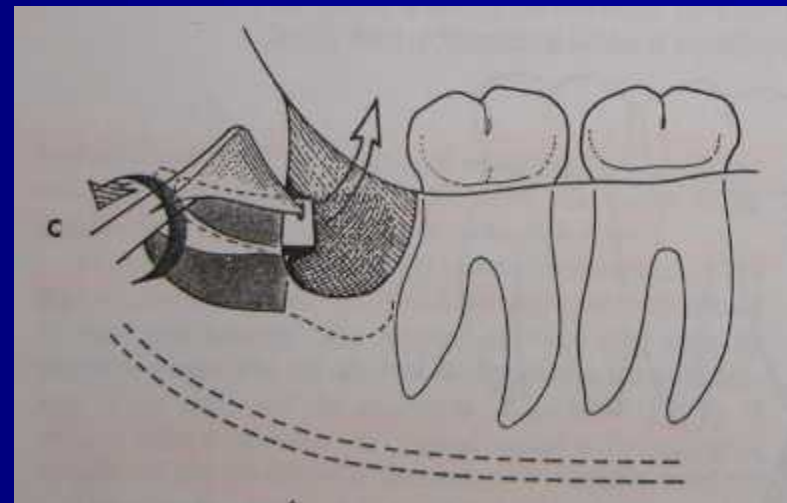
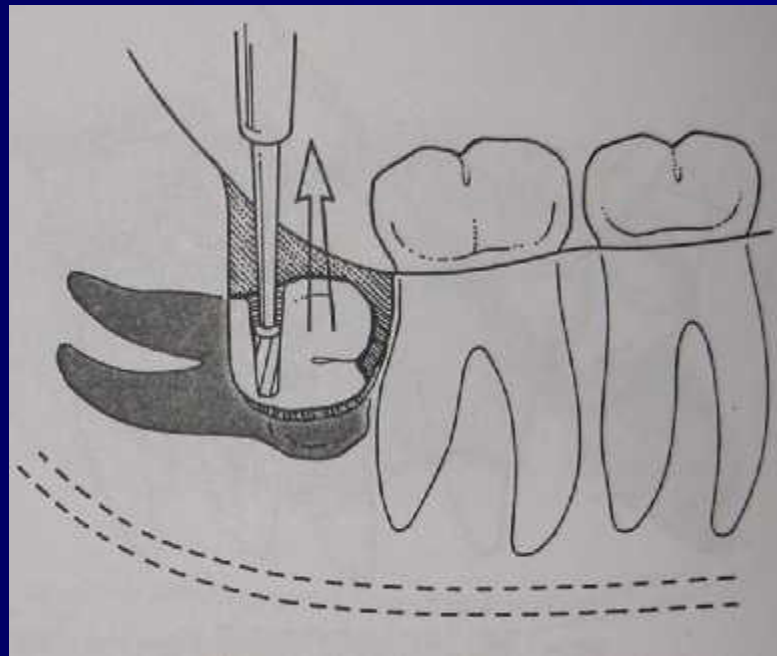




# Horizontal impaction

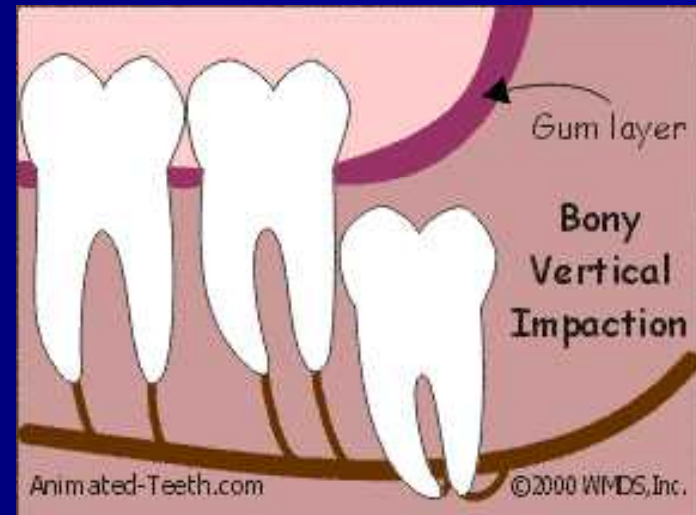
- Bone removal
- Divide crown from roots

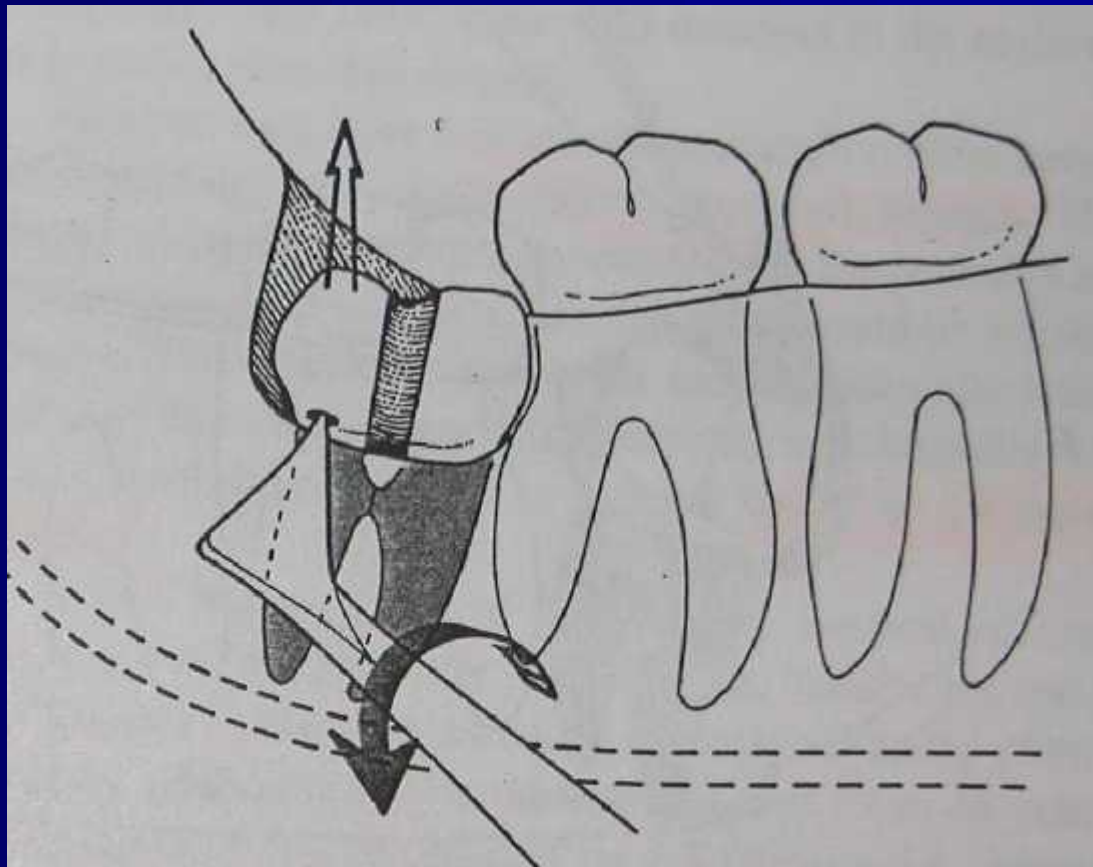




# Vertical impaction

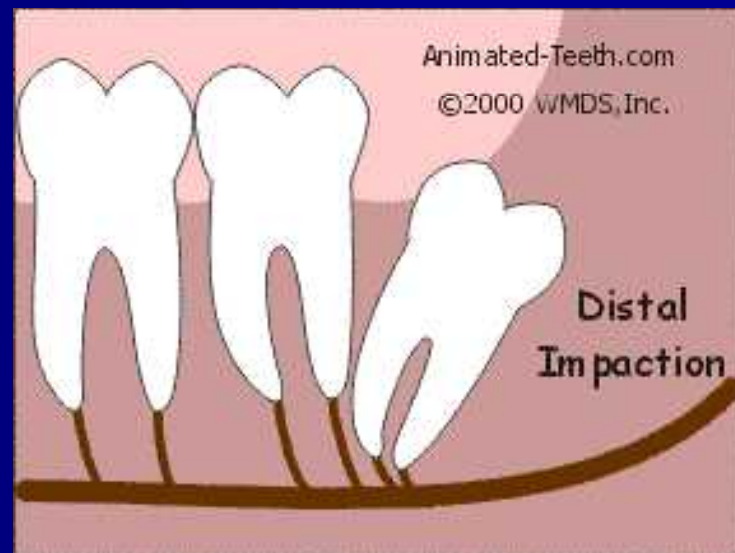
- Bone removal
- More access needed

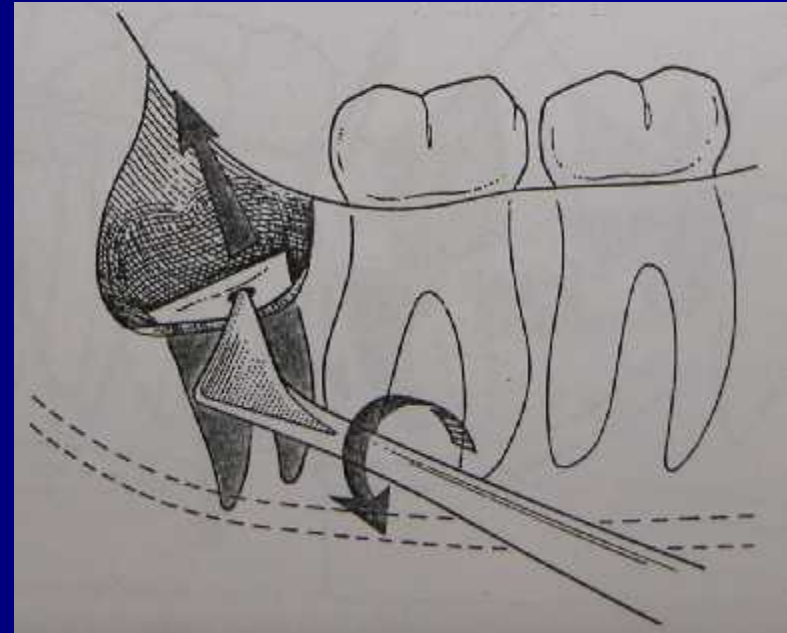
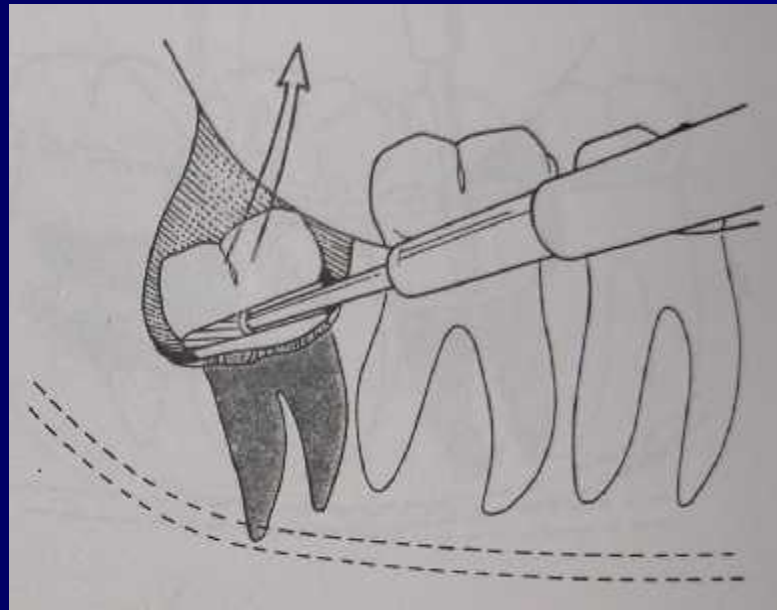




# distoangular

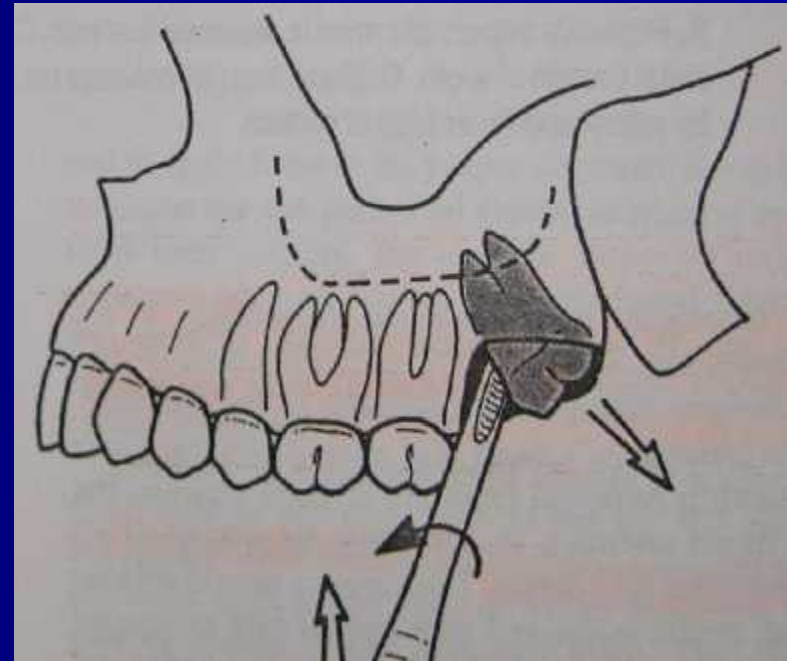
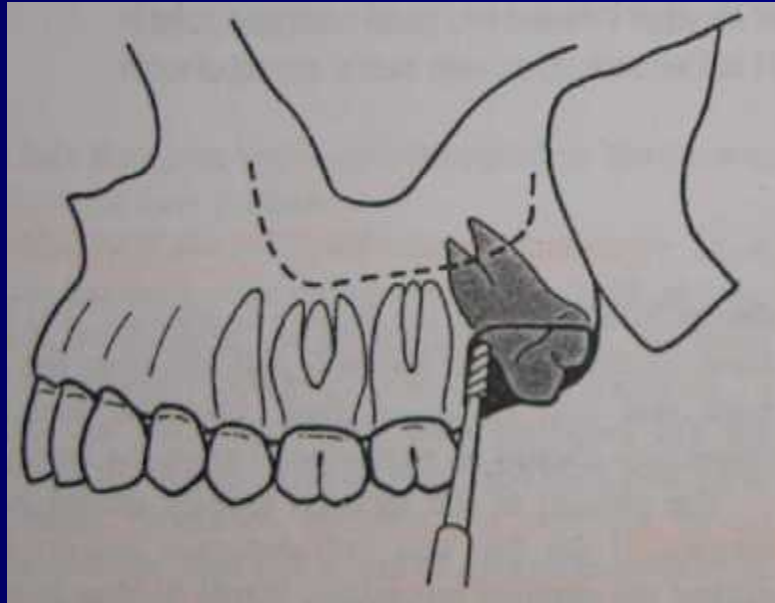
- Most difficult
- Bone removal
- Crown sectioning





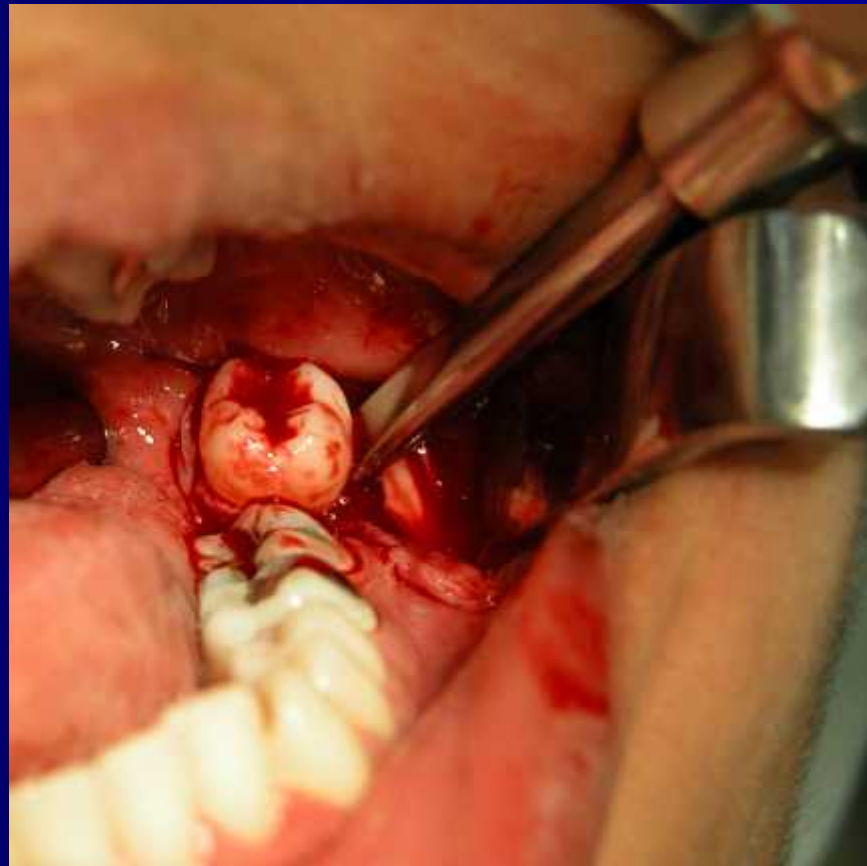
# Impacted maxillary teeth

- Rarely sectioned
- No chisel



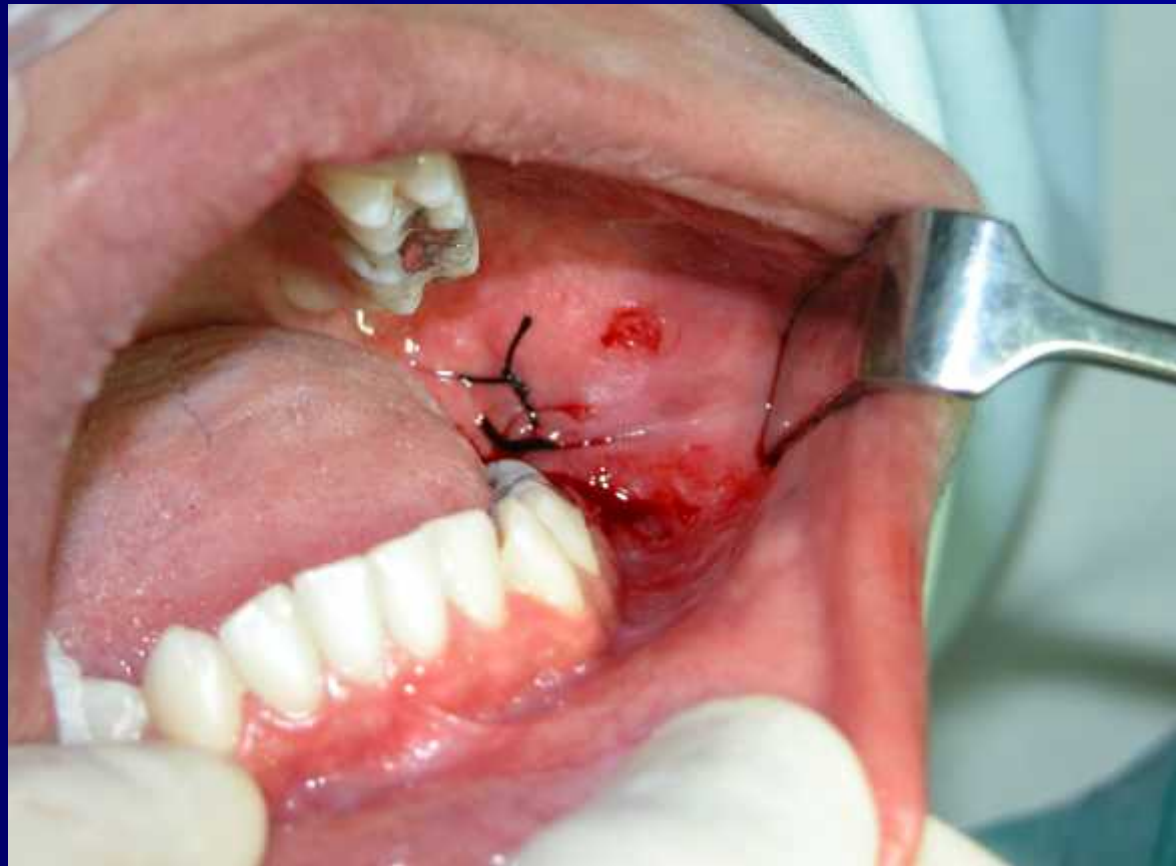# Basic steps

- Delivery with elevator
- No luxation
- No excessive force  
(maxillary and mandibular teeth)



# Debridement of wound

- Remove bone chips and debris
- Irrigate with saline
- Smooth sharp edges
- Primary closure



# Post-operative care

- Pain and anxiety control
- Steroids
- Antibiotics
- swelling

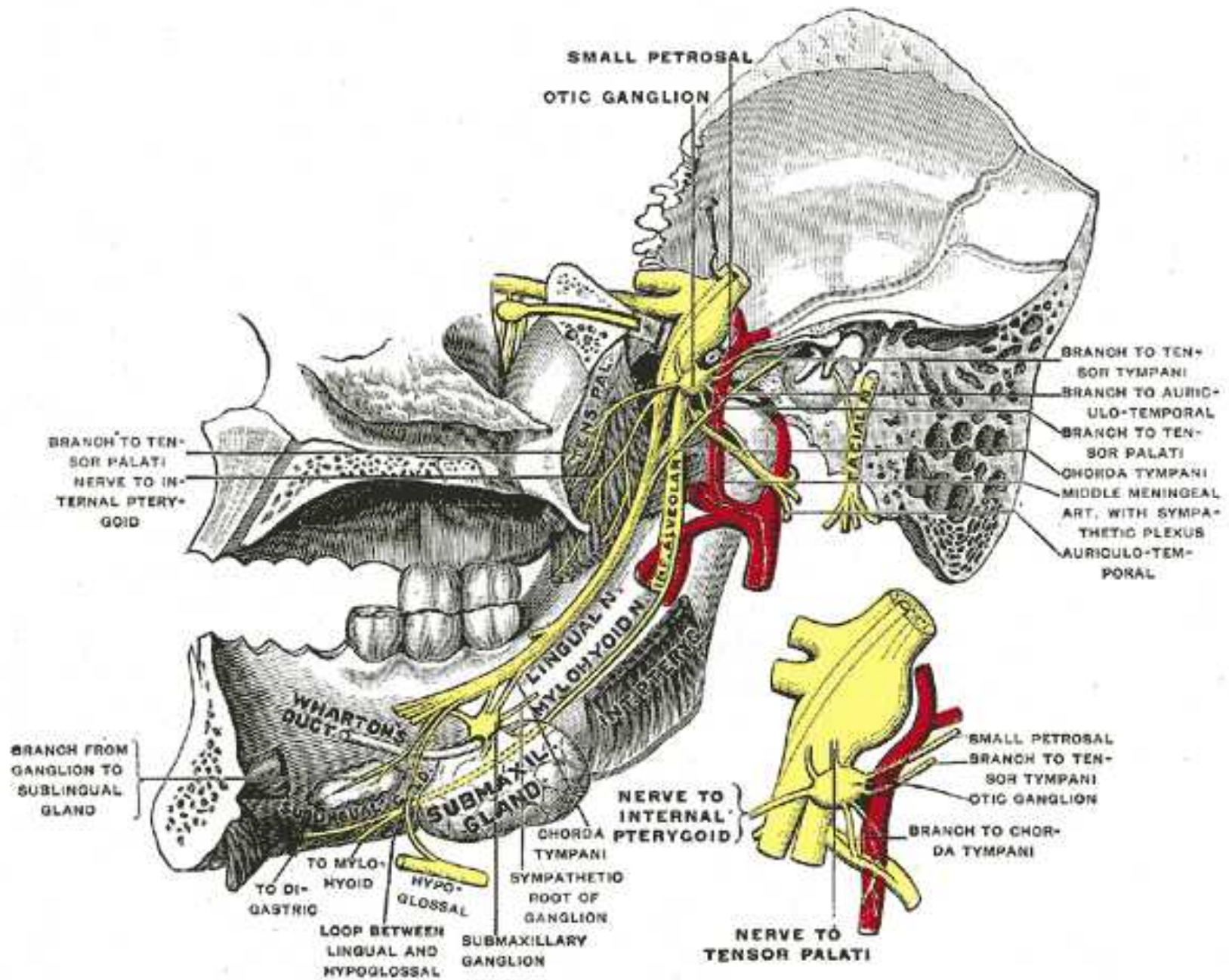
# Complications

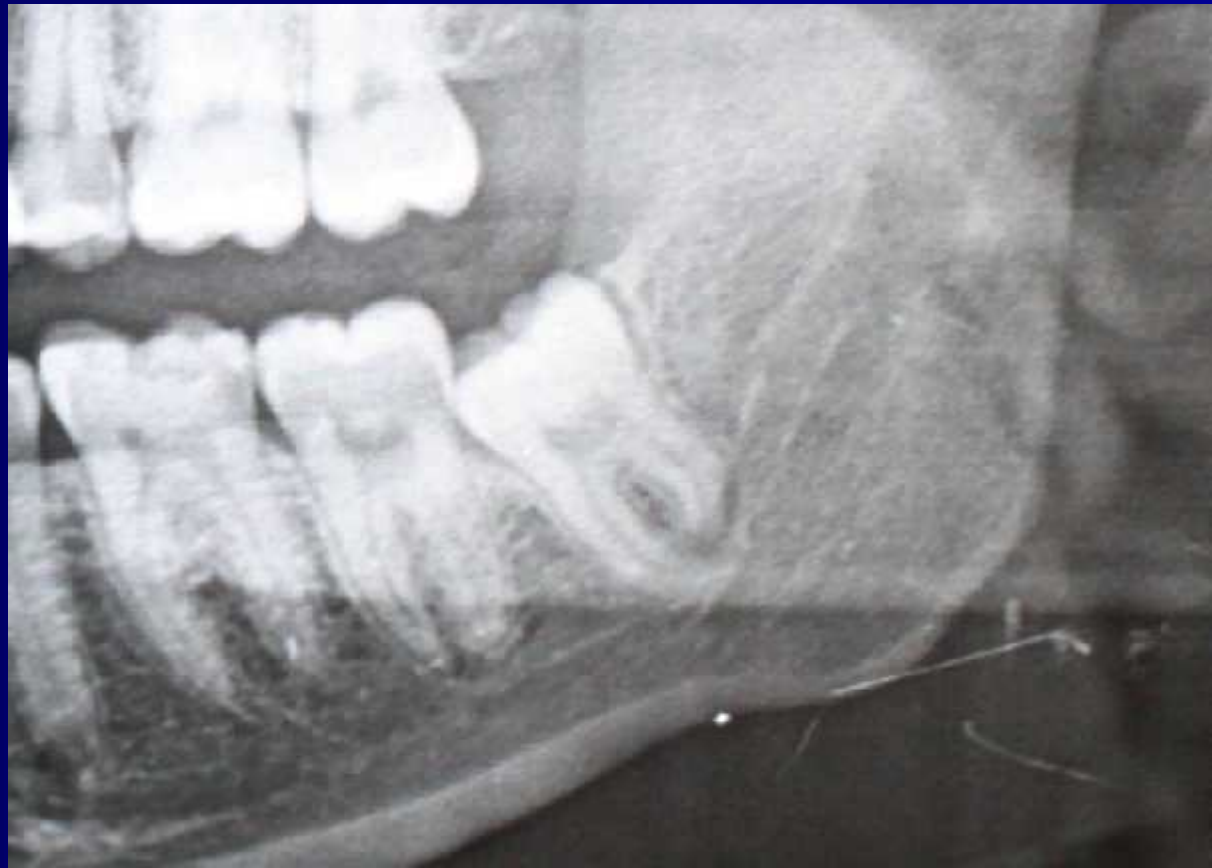# complications

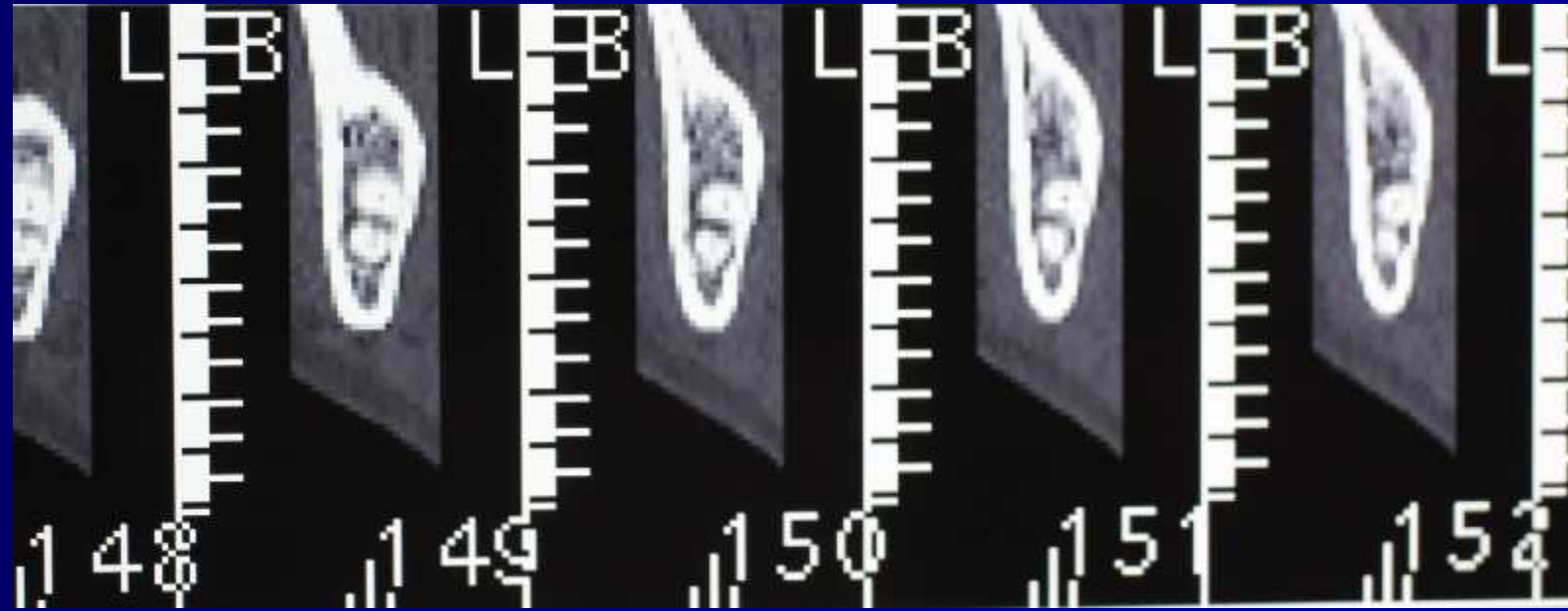
## Prevention

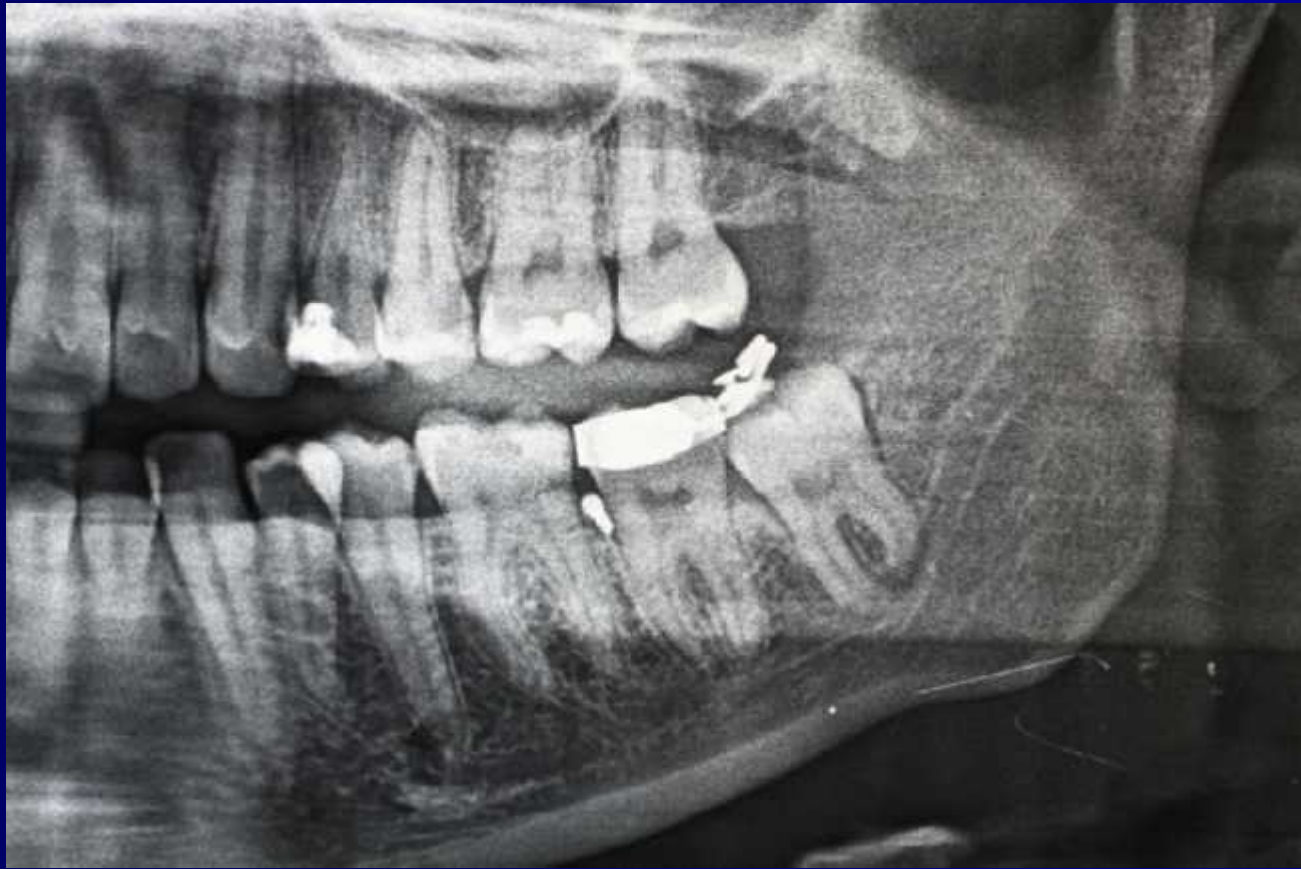### Intraoperative:

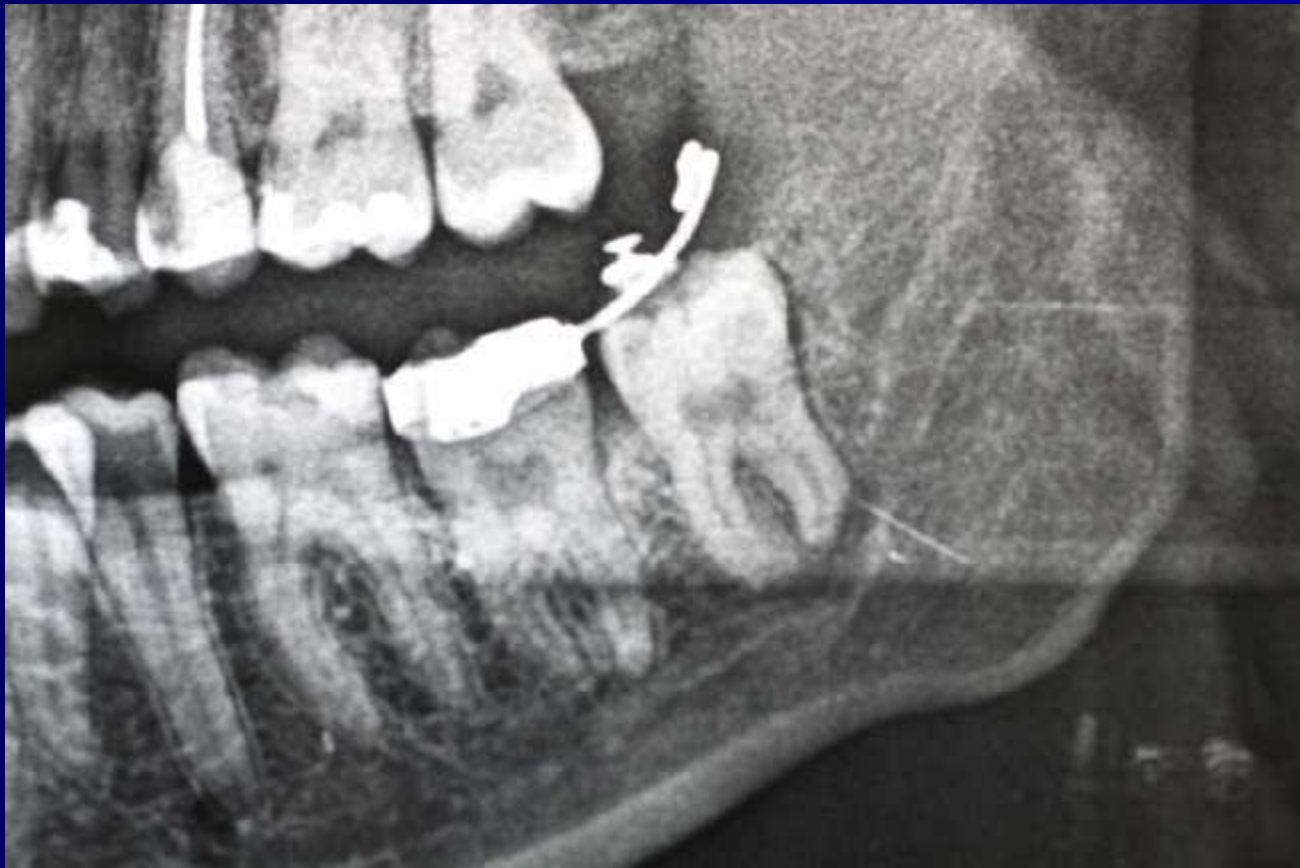- Soft tissue injuries
- Injuries to osseous structures
- Oroantral communications
- Fractures of the mandible
- Injuries to adjacent teeth
- Complications with the tooth being extracted
- Injuries to adjacent structures

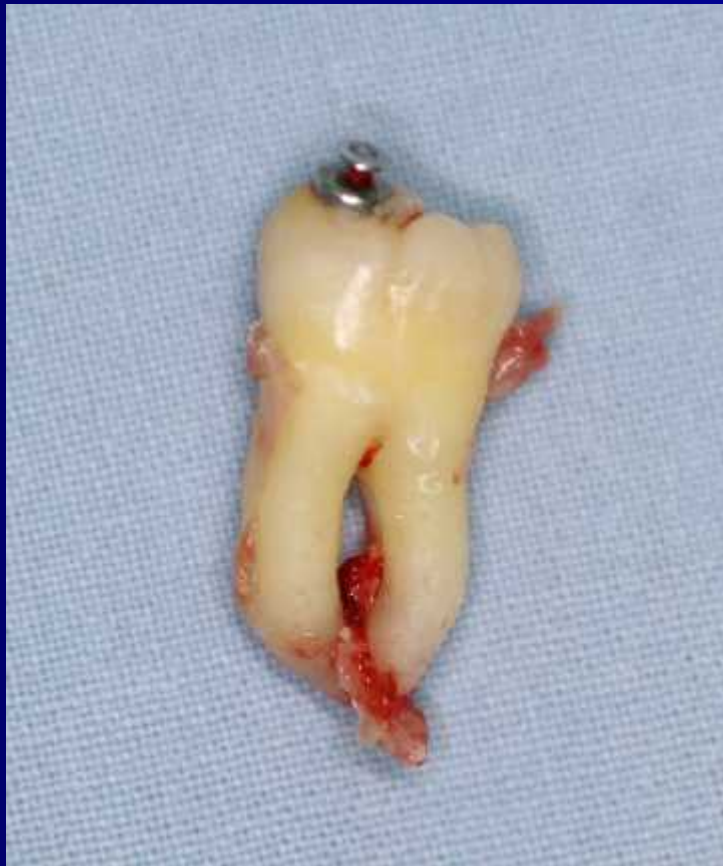











## Postoperative complications:

- Bleeding
- Delayed healing and infection



Thank you