

**Surgical extraction**  
*trans-alveolar extraction*

Zaid H Baqain

# Reference

Tooth extraction  
A practical guide

By Paul Robinson

*I will give you the relevant chapter*

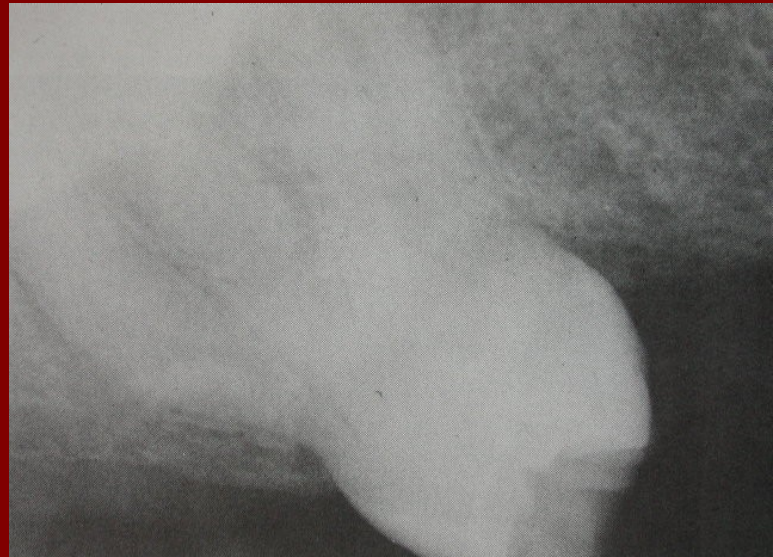
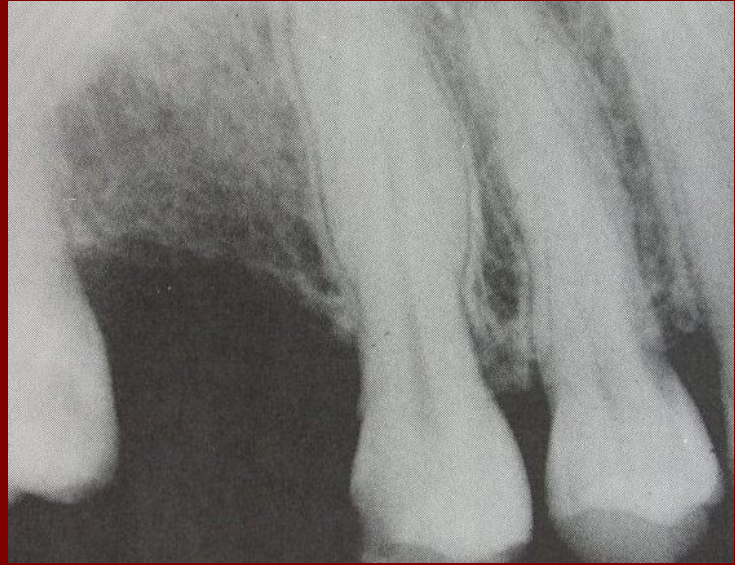
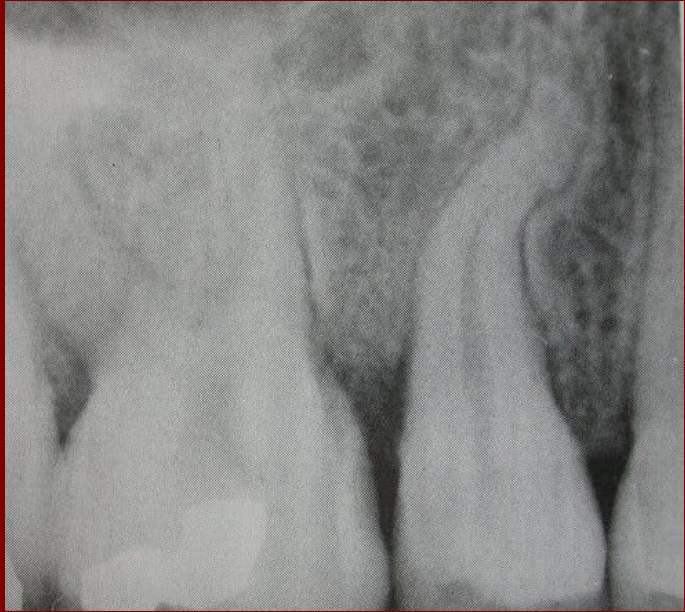
Some teeth are not suitable for removal using forceps, and this may be evident during preoperative assessment or during the course of attempted extraction.

# Surgical extraction:

“Gaining direct access to the alveolar bone and roots after raising the overlying soft tissues as a mucoperiosteal flap”

# Indications for surgical extraction

- Teeth resistant to normal extraction with moderate force
- Retained roots; cannot be grasped nor delivered using the elevator
- Impacted teeth
- Dense unyielding bone
- Hypercementosed or ankylosed teeth
- Abnormal teeth
- Multiple and unfavourable roots
- Teeth close to vital structures



# Mucoperiosteal flaps

## Principles of flap design

# Flap

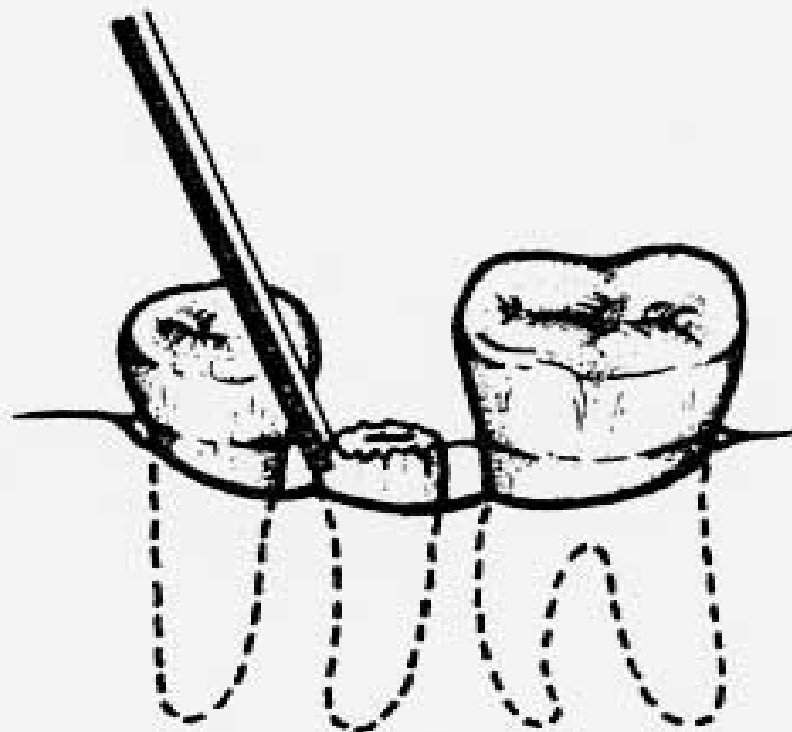
- Outlined by a surgical incision
- Carries its own blood supply
- Allows surgical access to underlying structures
- Replaced in the original position
- Can be maintained in sutures and is expected to heal.

# Shape of flaps

# Gingival flaps

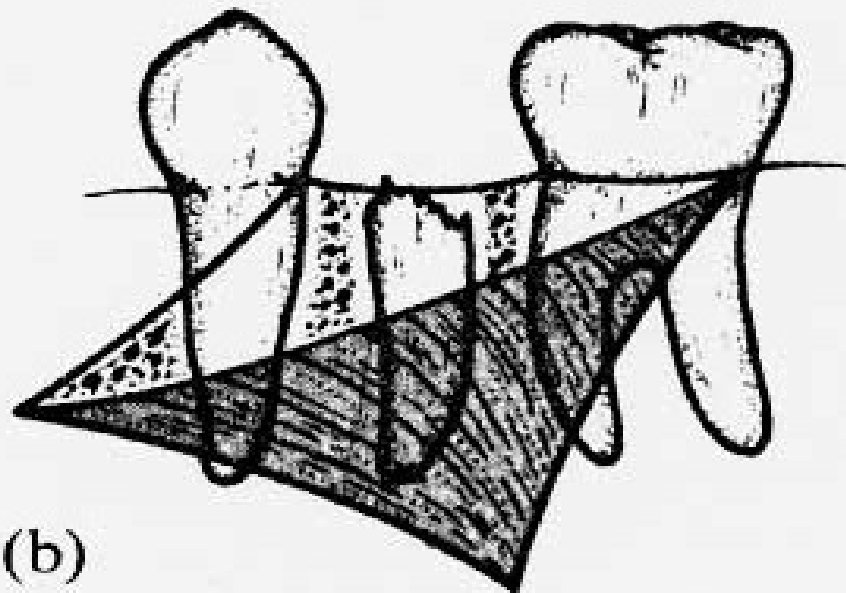
- One incision along the gingival margin
- Offers restricted access to the hard tissues at the crest of the alveolus
- Risk of stretching and tearing the soft tissues, therefore 2 teeth anterior and 1 tooth posterior
- Useful to apply elevators for cases that do not require bone removal

(a)

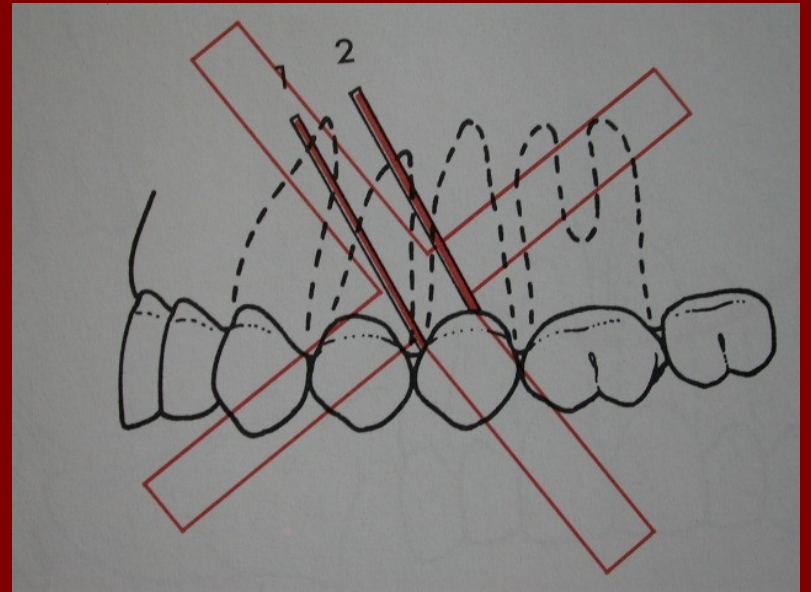
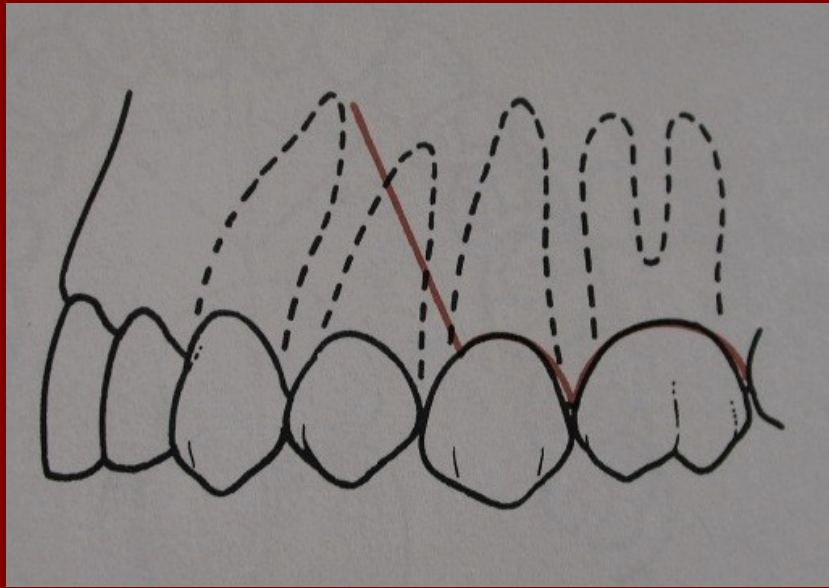


# Two-sided flaps

- One incision along the gingival margin and another (relieving incision) angled obliquely across the attached buccal gingiva into the lax vestibular mucosa (usually anteriorly).
- Relieving incision should not be straight vertical and should be away from bony prominences (to avoid tension when closing).
- Gives adequate access to most surgical extractions.

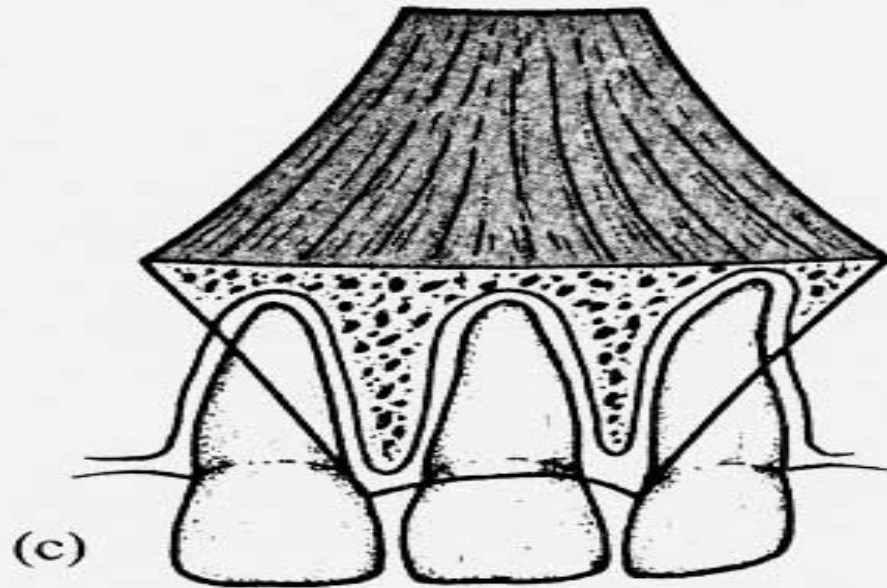


(b)



# Three-sided flaps

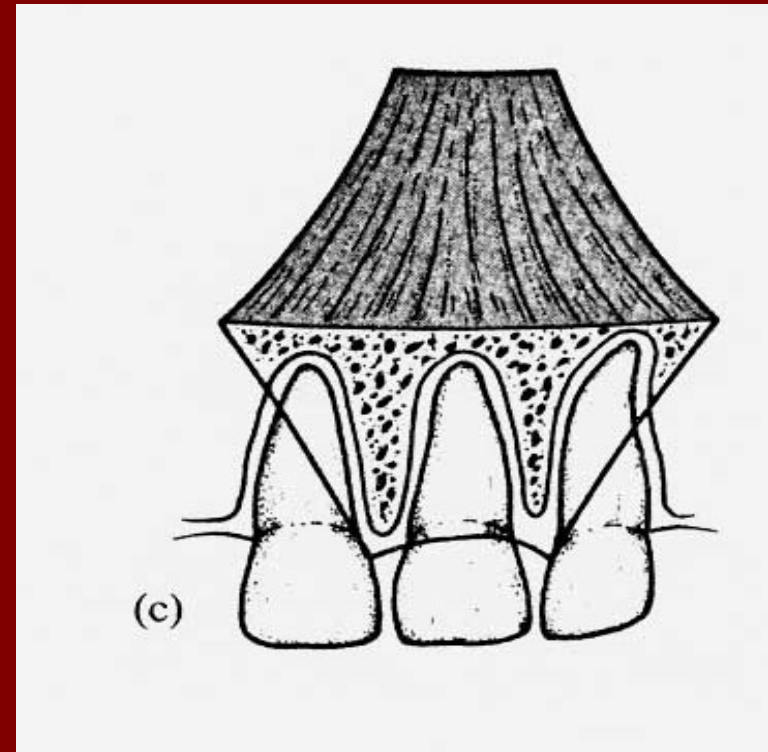
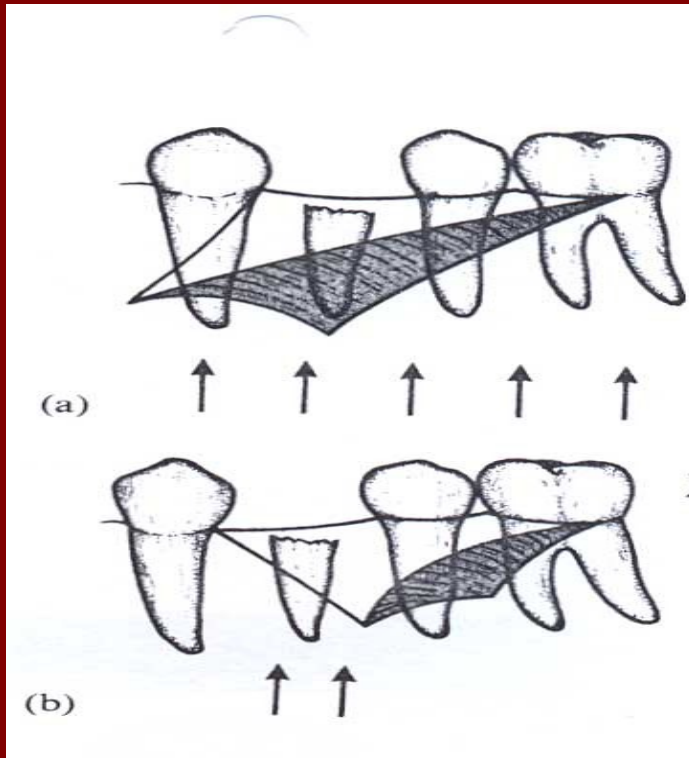
- Have second relieving incision at the distal end of the flap.
- Allows extra mobilization of the soft tissues and greater exposure of bone and roots.
- Useful for apicectomies and closure of OA fistulas



# Design parameters for soft tissue flaps

# Blood supply

- Base wider than the free margin



# Access

- Flaps should be large enough to permit clear access to the site (visualization) without the need to stretch and tear the tissues.
- Allow insertion of instruments.
- Allow placement of retractor

# Avoiding vital structures

- The relieving incisions
- In the mandible 2 vital structures!!??

# Suture over bone

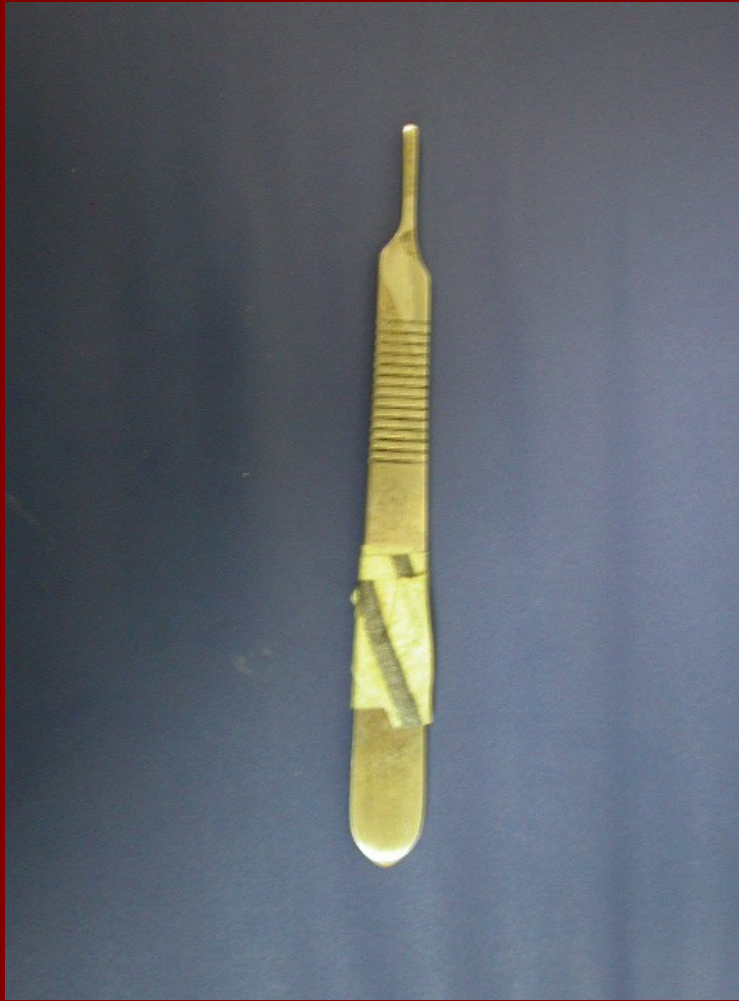- Margins of the flap should be as far as possible from the intended bone removal site.

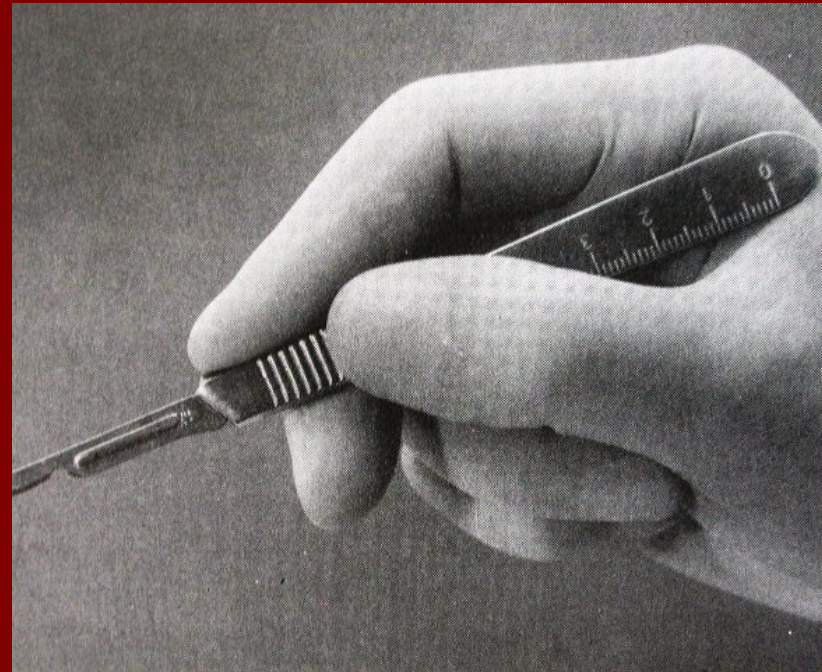
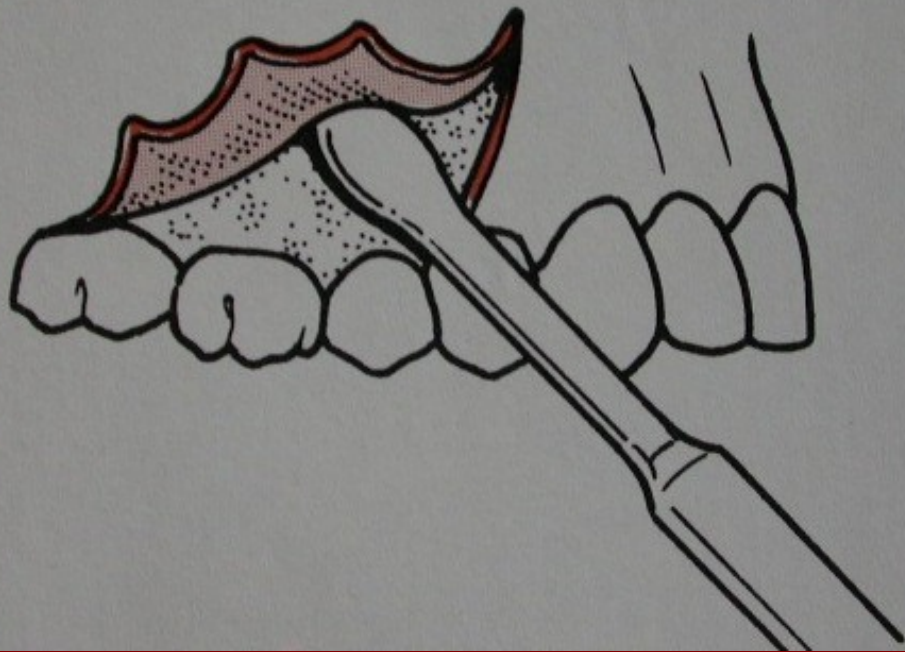# Ease of closure

- Placement of the flap edges.

# Making the incision

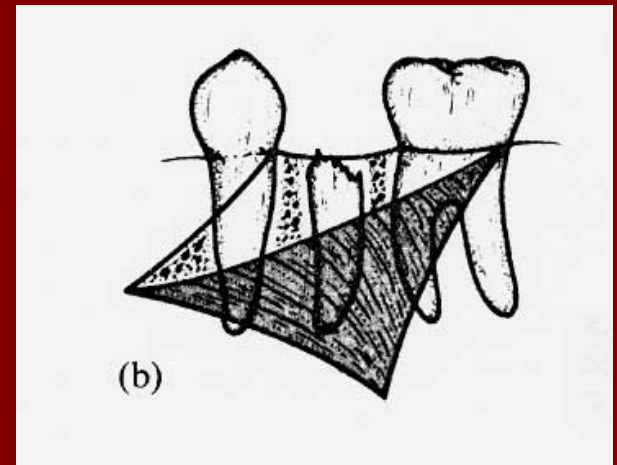
- Using a scalpel and number 15 blade.
- Firm, positive pressure so that all layers of the soft tissues are divided at a single clean, careful stroke.
- Relieving incision should always cross the mucogengival junction.
- Blade always at right angle to the surface of the mucosa.





# Raising the flap

- Should include mucosa, submucosa and periosteum.
- The full thickness of the flap (mucoperiosteum) is elevated from the underlying bone starting from the anterior relieving incision



- Elevation of the flap should be carried out on a broad front.
- Care around sinus tracts on the buccal flap.

# Bone removal

“ a precious commodity”

- To expose the tooth and clear its path of exit
- To provide suitable point of application

## After extraction

- To remove sharp edges
- To smooth the ridge contour to assist the Prostodontist

- Instruments;
  - Dental bur, in a straight handpiece
  - Chisels or gouges
  - Rongeurs or bone nibblers



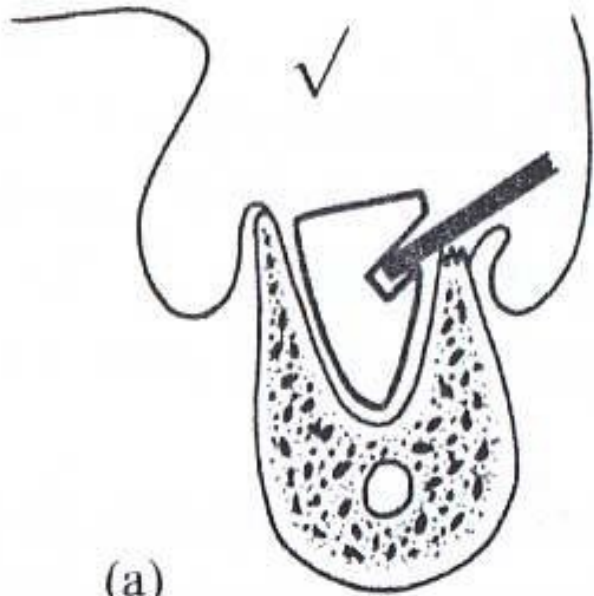
# Rotary cutting instruments dental drills and burs

- High torque at bur speeds of 1000-30 000 rpm
- Straight handpiece
- Tungsten-carbide tipped burs or sharp new SS burs (Rose head or round burs and fissure burs)
- Coolant (normal saline)

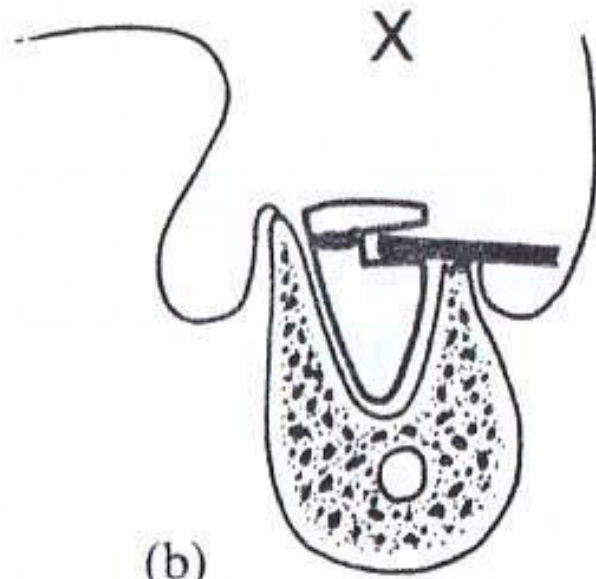
# Tooth removal

- After reflection of a flap try the following in single rooted teeth:
  - Reseat the extraction forceps
  - Grasp a bit of the buccal bone with the buccal beak of the forceps
  - Force a straight elevators down the periodontal space (wedging)
  - Finally,,,bone removal

- Making a point of application
  - *“give me a lever and a secure fulcrum and I will move the world”*
  - Usually a point of application is created in bone
  - Takes into consideration the shape of the roots and the path of displacement of the tooth

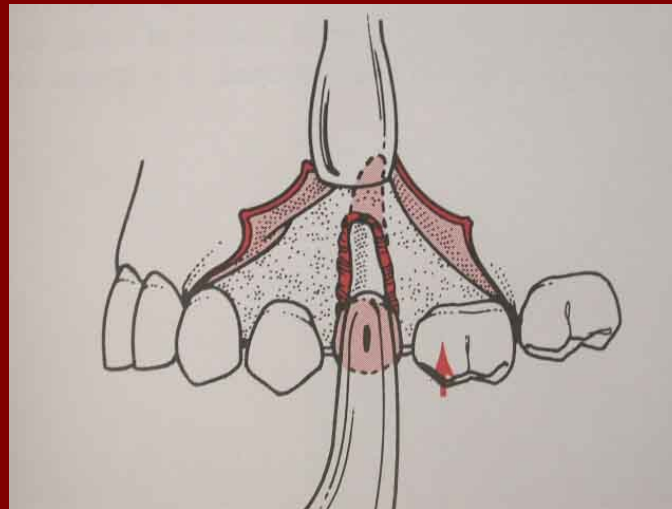
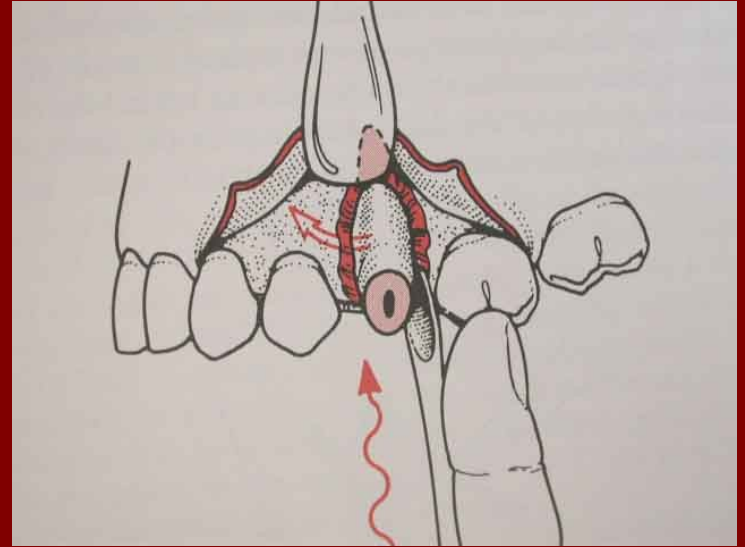
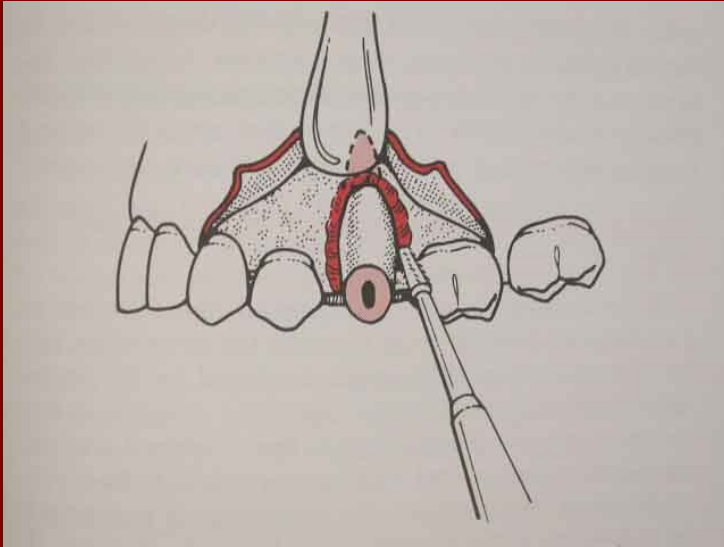


(a)



(b)

# Single rooted tooth



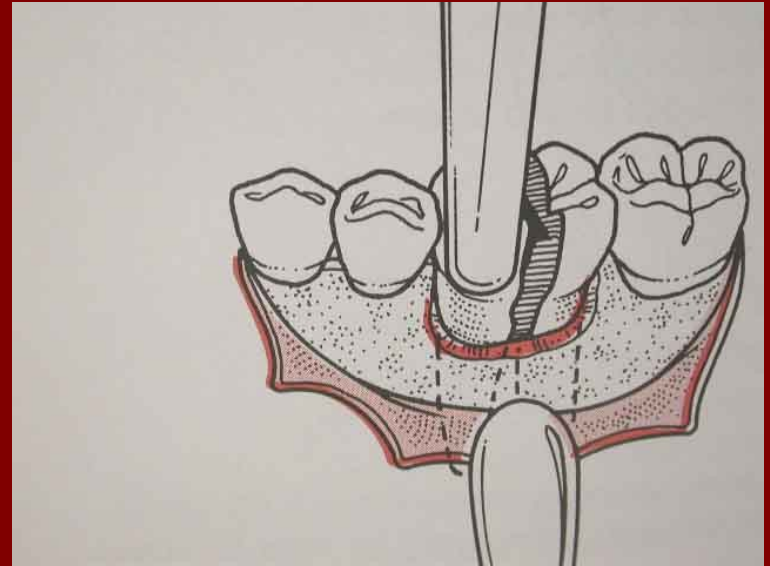
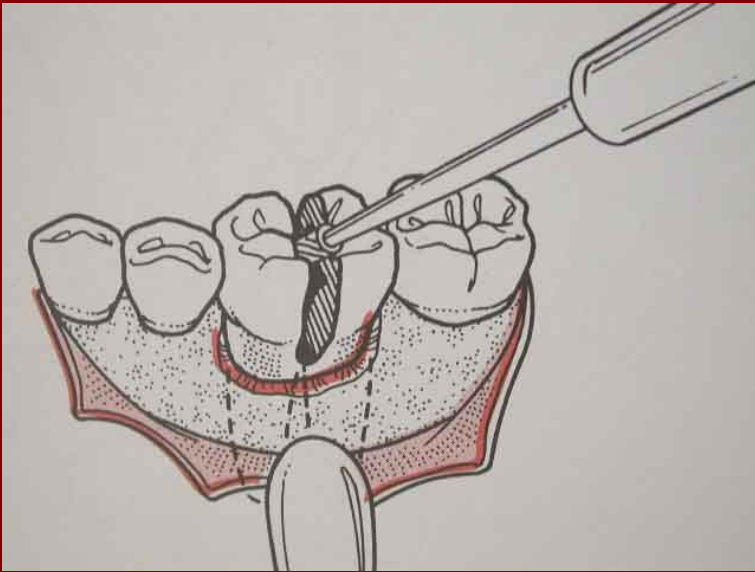
# Tooth division

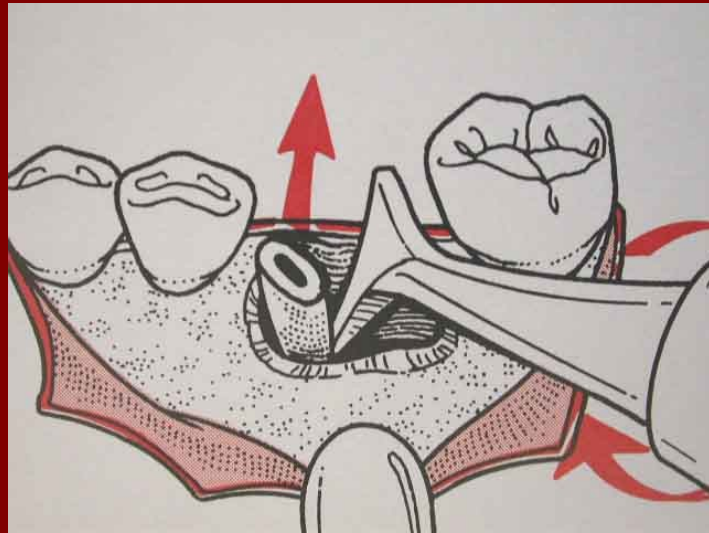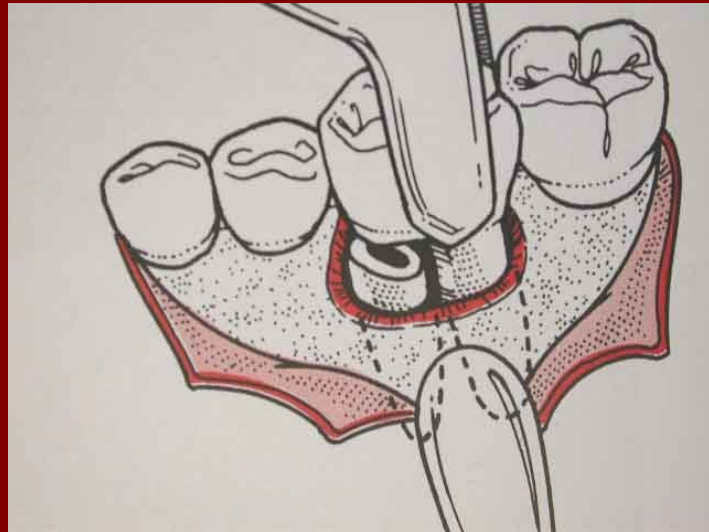
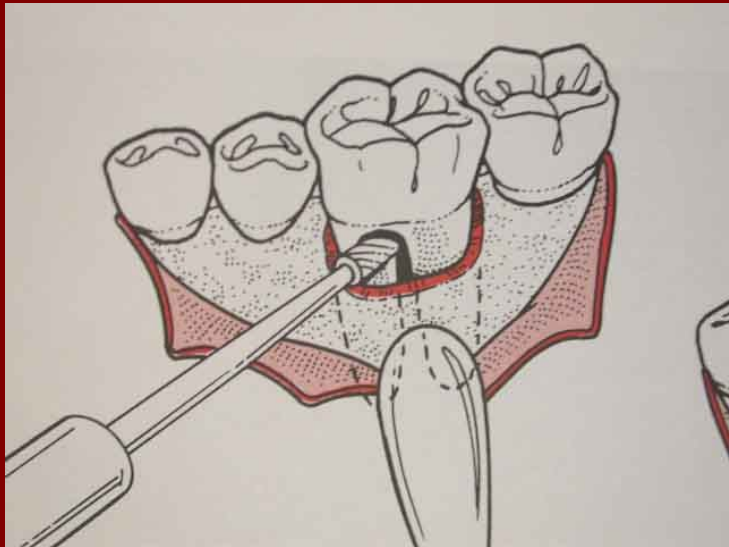
Indicated when the intact tooth is resisting displacement, yet the parts of the tooth could be readily displaced after separation from each other.

# Roots widely divergent

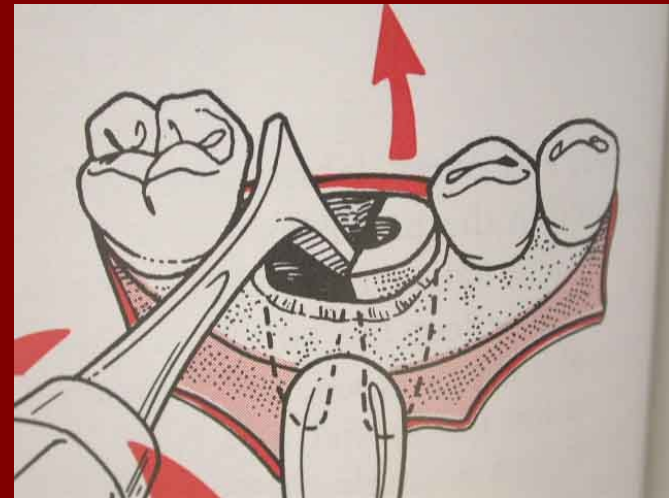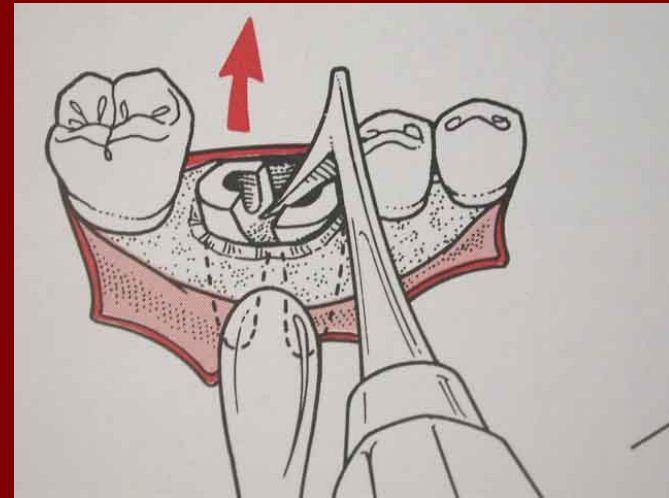
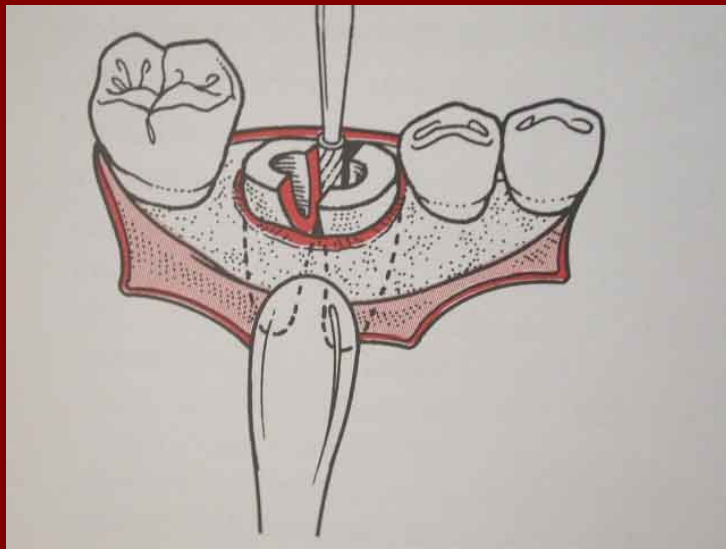
- Different paths of withdrawal.
- Lower molars
- Sectioning the crown first then the roots using a fissure bur, starting at the bifurcation and moving coronally.
- Once separated the individual roots are displaced along its own path of withdrawal using a small elevator (like number 1 Coupland)

# Lower Molar

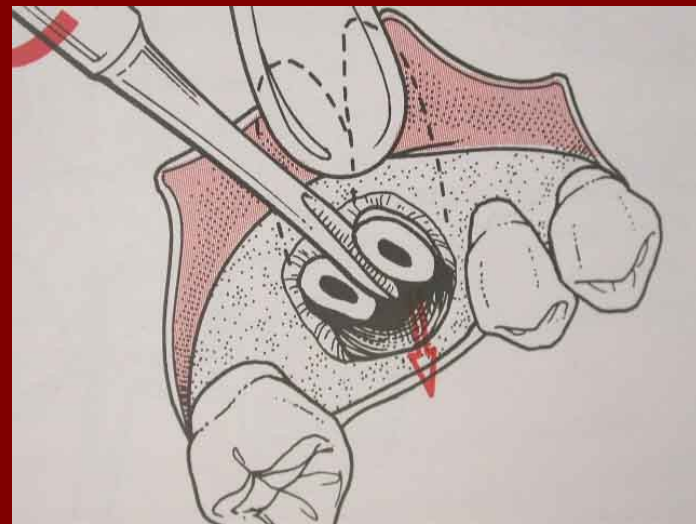
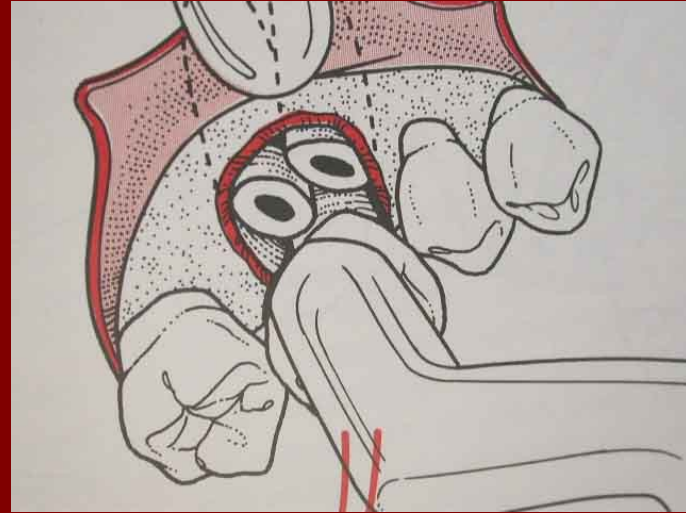
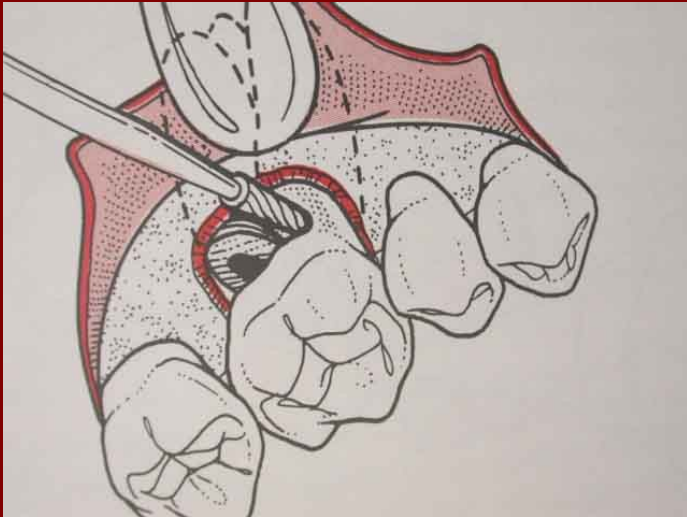




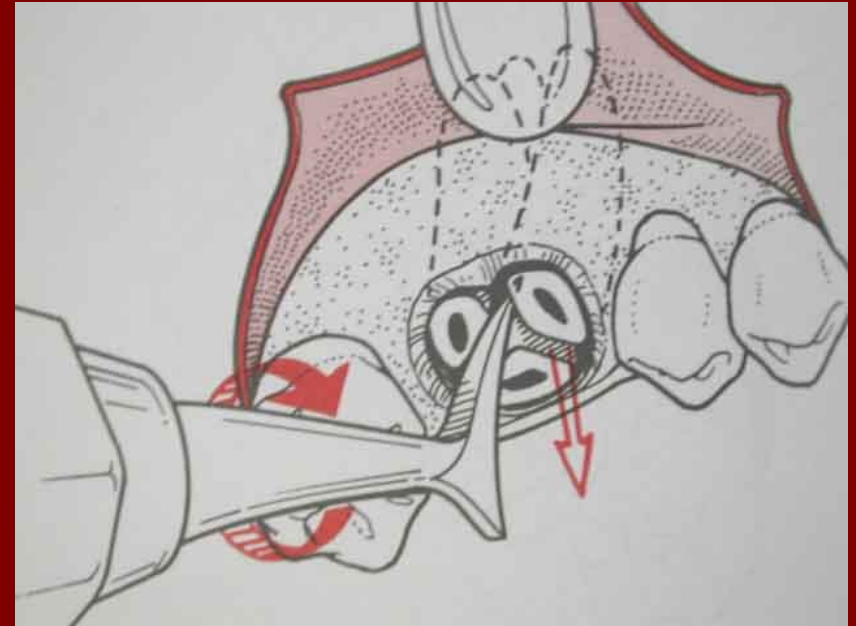
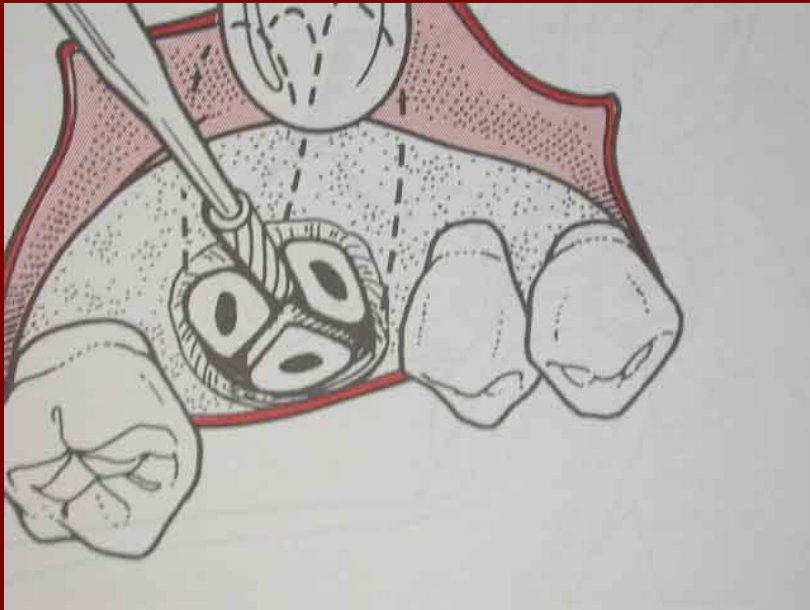
# Lower molar remaining roots



# Upper molars



# Upper molar remaining roots



- In multi rooted teeth, the most difficult root to elevate is the first one
- The socket of the first root is used as a deeper application point for the second root using a curved elevator.

- Before dividing the teeth, it is advisable to remove enough bone round the roots to provide suitable application point for elevation.
- Much easier to see where bone removal is required with the tooth intact.

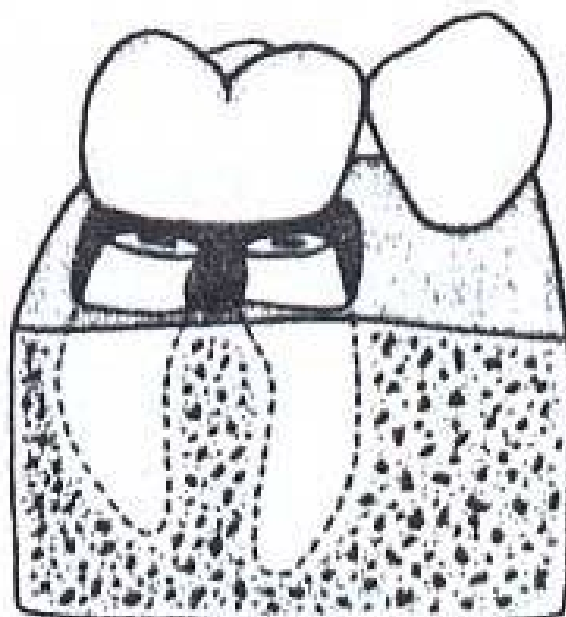
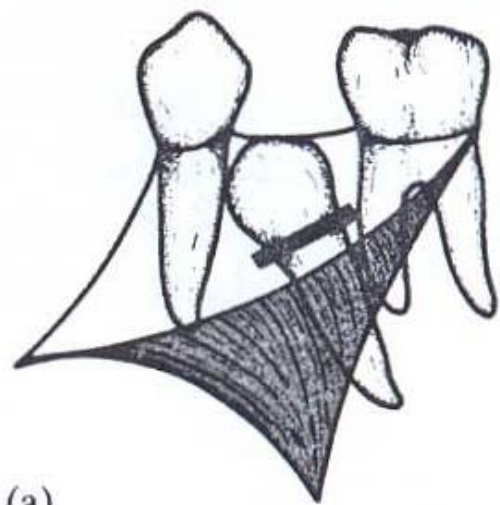


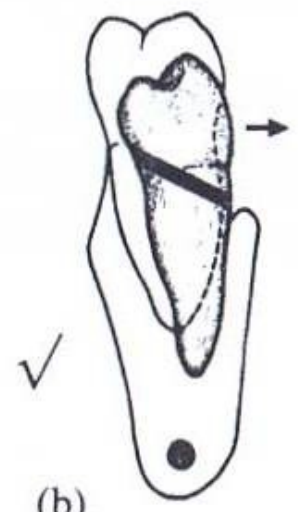
Figure 3

# Impacted teeth

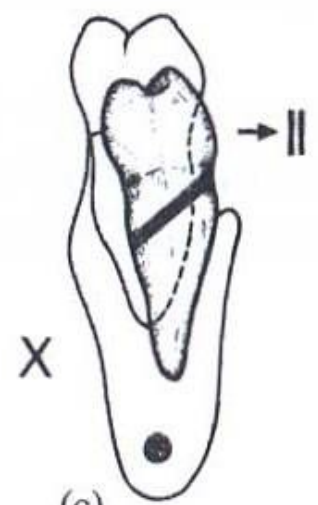
- When the path of withdrawal is blocked by the adjacent tooth in the arch. E.g. lower second molars
- Sectioning the crown with a fissure bur, facilitate the removal of both. This minimizes bone removal, and creates enough space to allow the crown to come out buccally.
- The direction of sectioning is important, so that the lingual portion does not end up being larger than the buccal portion.



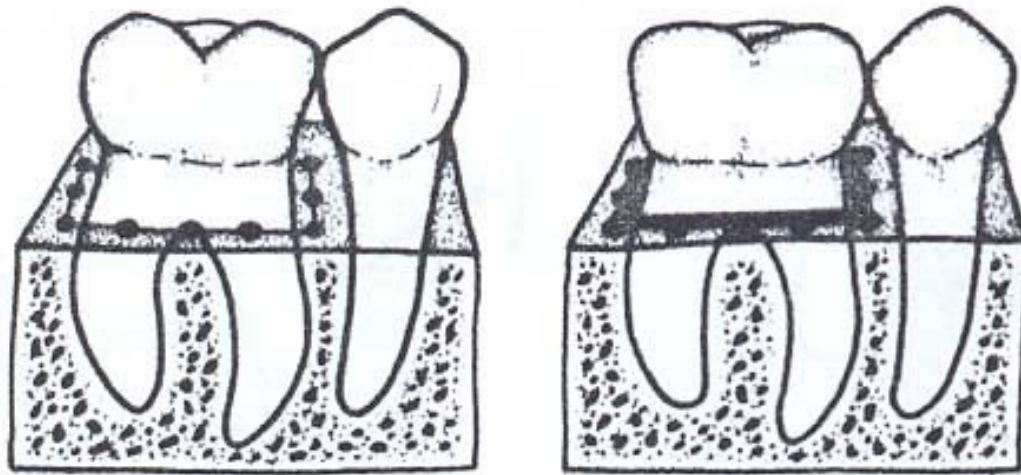
(a)



(b)



(c)



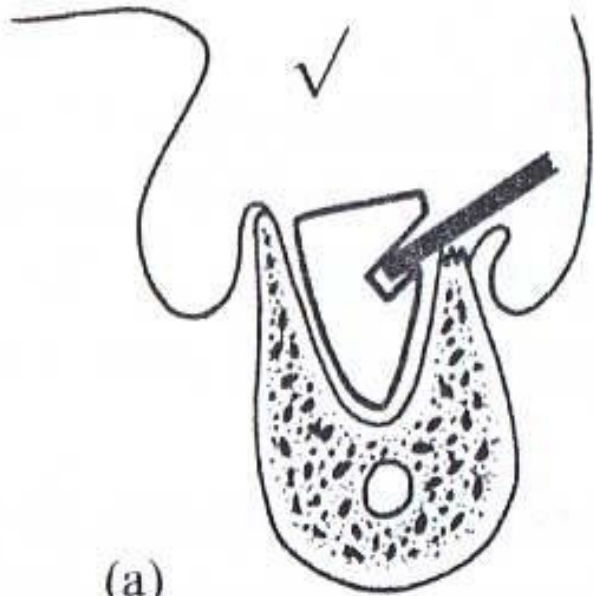
**Figure 3.9.** Removal of a block of bone by the

- Osteotome can be used in the hand of the experienced operator.
- Quicker but has several disadvantages:
  - Little space is created for movement between the separated fragments.
  - Tooth may not split along the intended line
  - Not safe in the inexperienced.

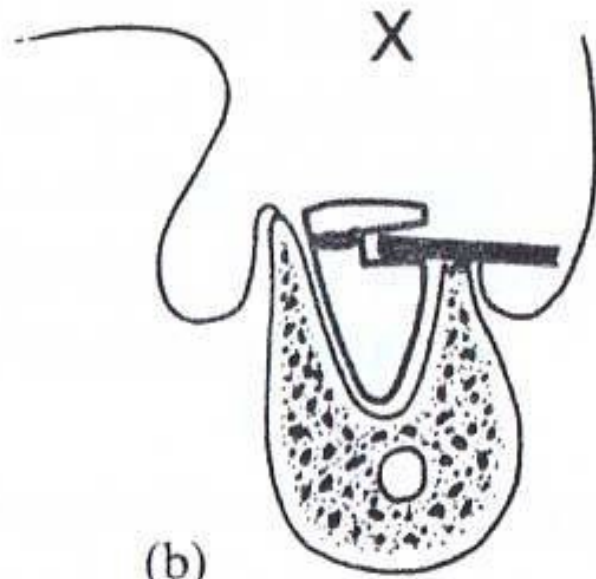
- Not all the teeth are suitable to be divided and some cases sectioning can make the root removal even more difficult.
- This is true of teeth where the only safe, solid and accessible point of application for an elevator or the best position to grasp the tooth with forceps, is by its crown.
- E.g. distoangular impacted lower third molars, impacted upper second premolars in the palate.

# Elevation of roots

- Removing bone provides optimal application point for elevation.
- Sometimes it is possible to reach the root with a fine bladed forceps.
- Sometimes a decision has to be made regarding leaving a small root fragment in situ.
- Most roots left cause n complications unless large and prevents the socket from healing, or root is infected.

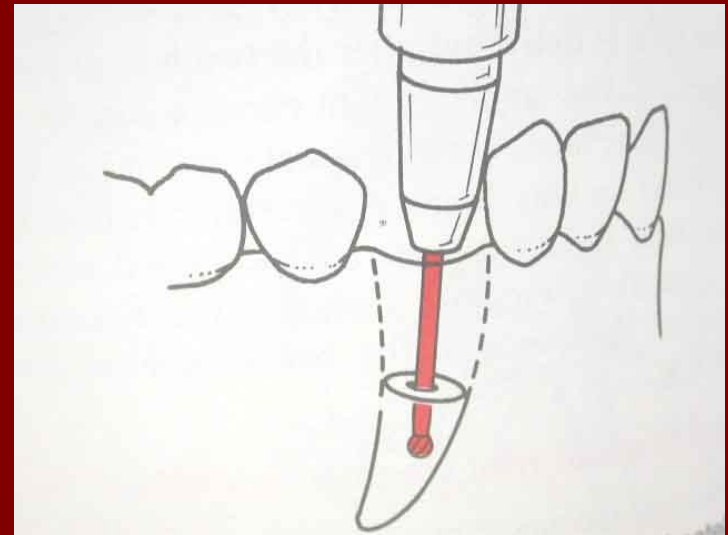
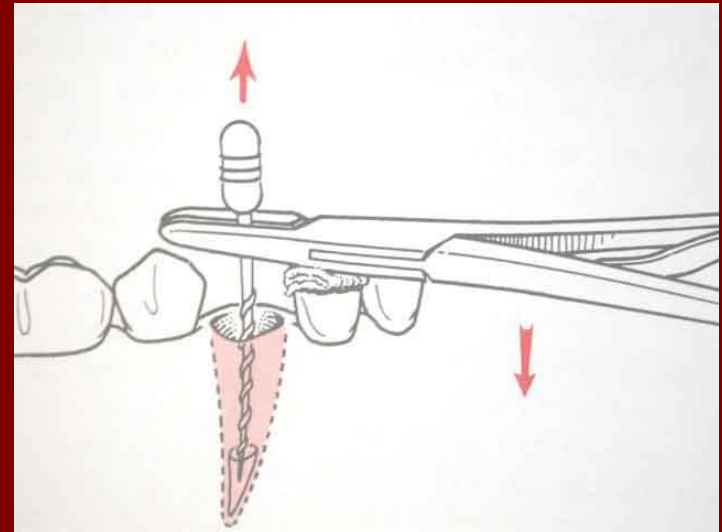
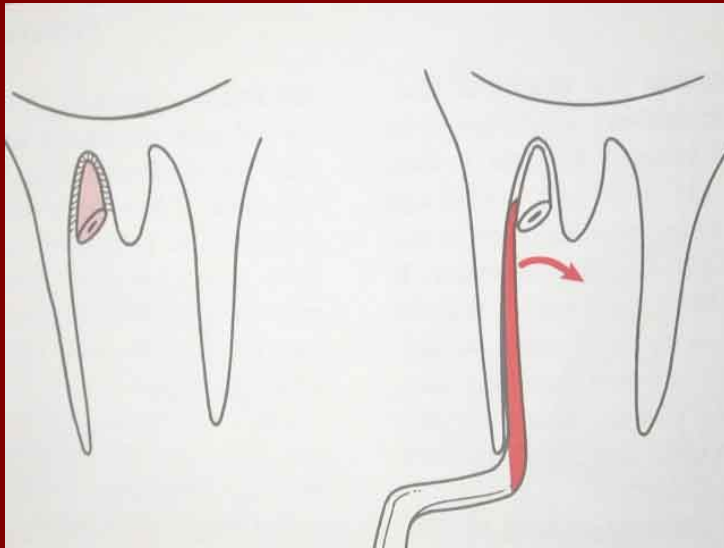


(a)



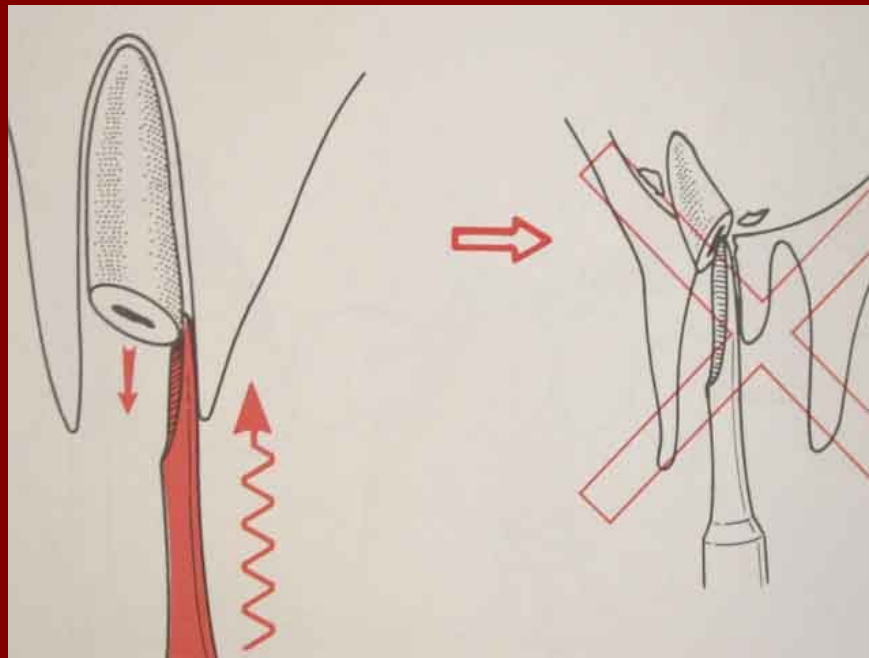
(b)

# Remaining roots

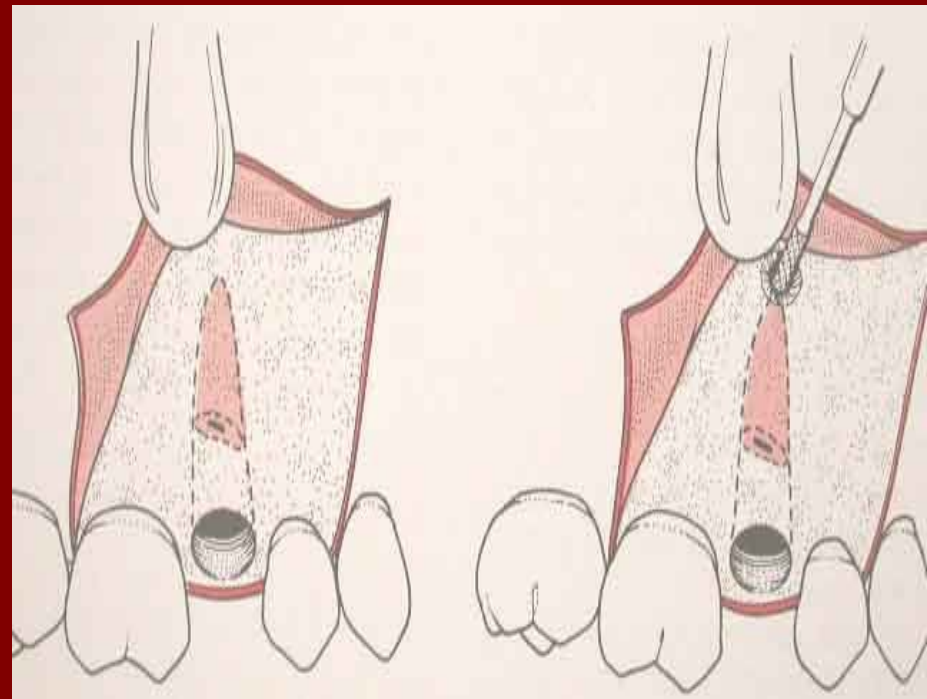
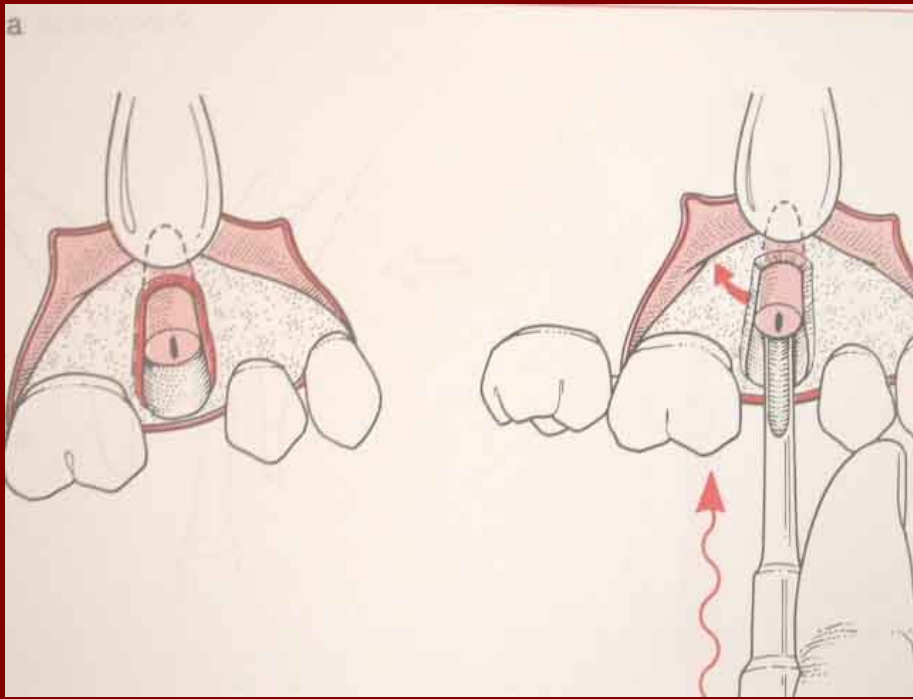


- Non vital roots and roots dislodged elsewhere during extraction should ideally be removed as they become a nidus for infection.

Always use the elevator with care



# Surgical removal of remaining roots

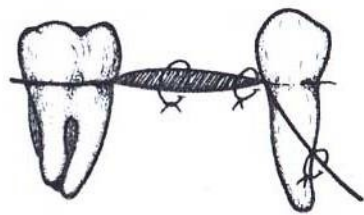


# Following tooth removal

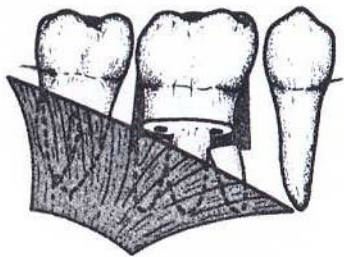
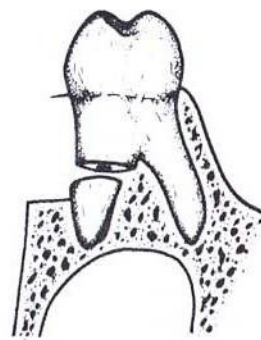
- 1. Debridement of the socket:
  - To clean and check for pieces of debris that could impede healing.
  - Aspiration using vacuum suction and a fine surgical sucker to inspect the socket
  - Fine curved artery forceps to remove large fragments.
  - Irrigation with a sterile saline is helpful to provide clear view and to flush out small particles.

- **Gentle** curettage with a curette removes remnants of adherent infected granulation tissue.
- Unwanted bony prominences reduced with rongeur bone nibblers or acrylic bur at slow speed.

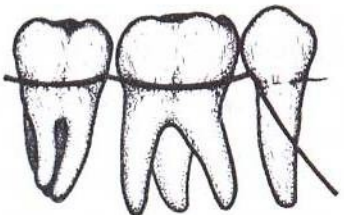
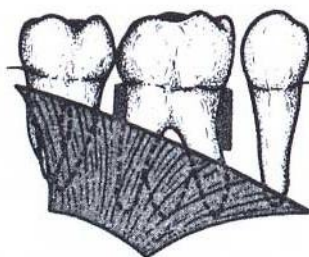
- 2. suturing:
  - To replace and secure the mucoperiosteal flap in its place.
  - To limit the size of the wound restricting contamination.
  - To assist controlling haemorrhage
  - To repair oro0antral fistula.



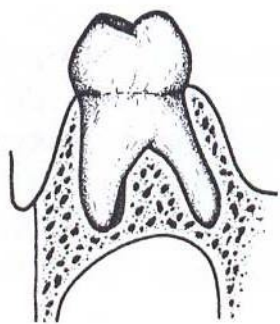
(j)

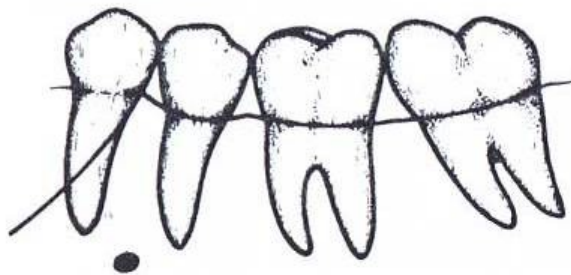


(p)

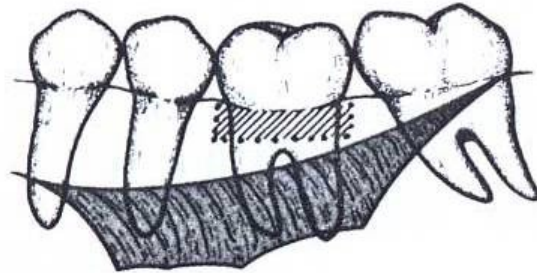


(q)

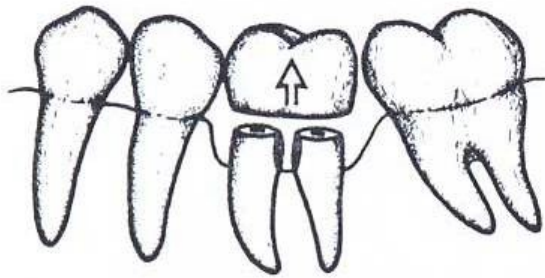




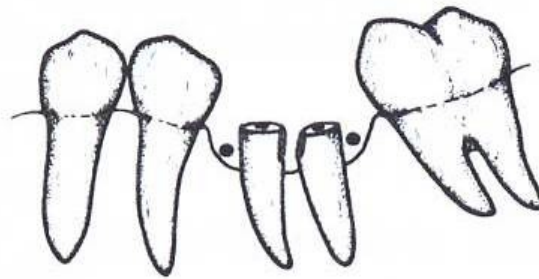
(a)



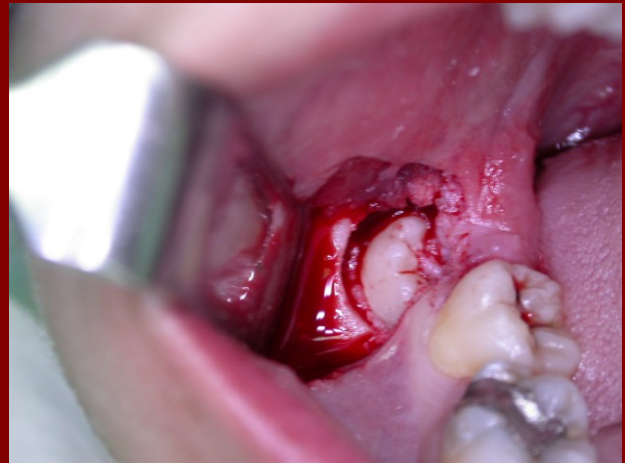
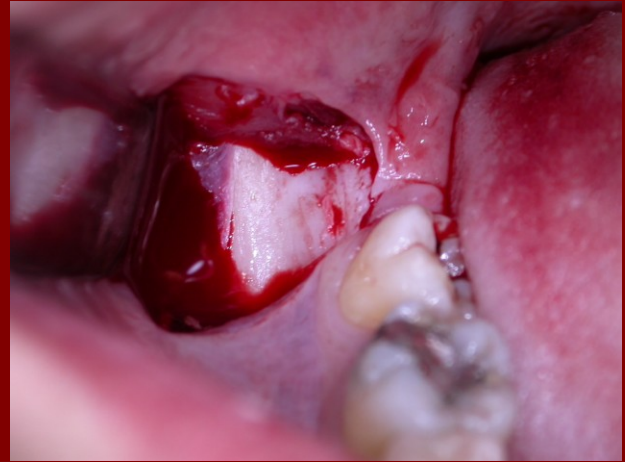
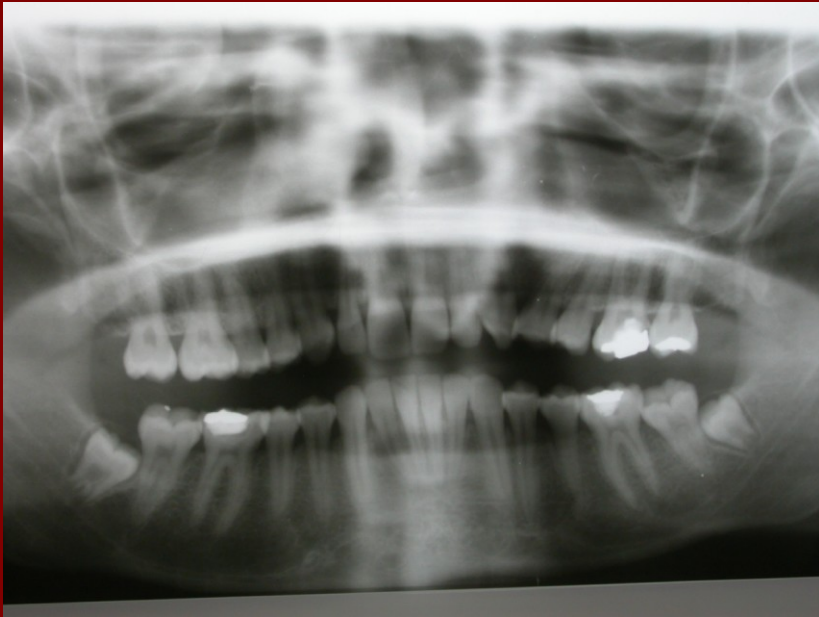(b)

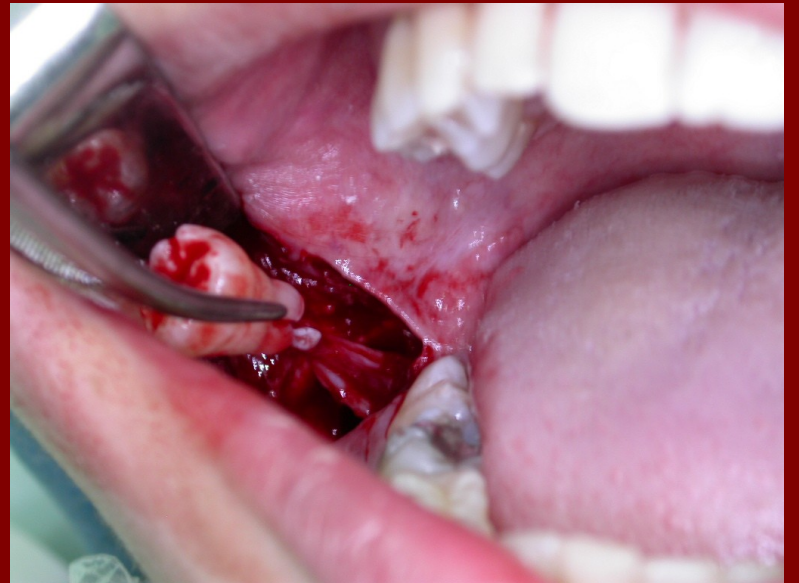
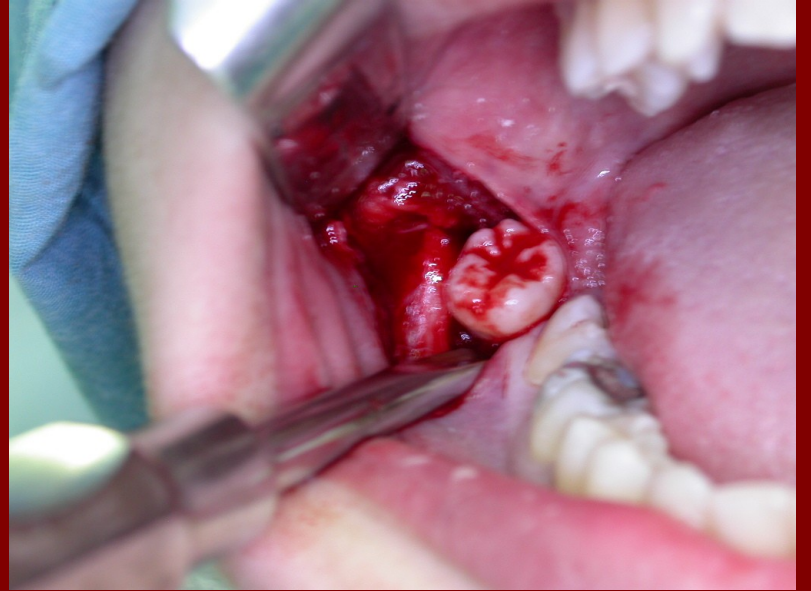
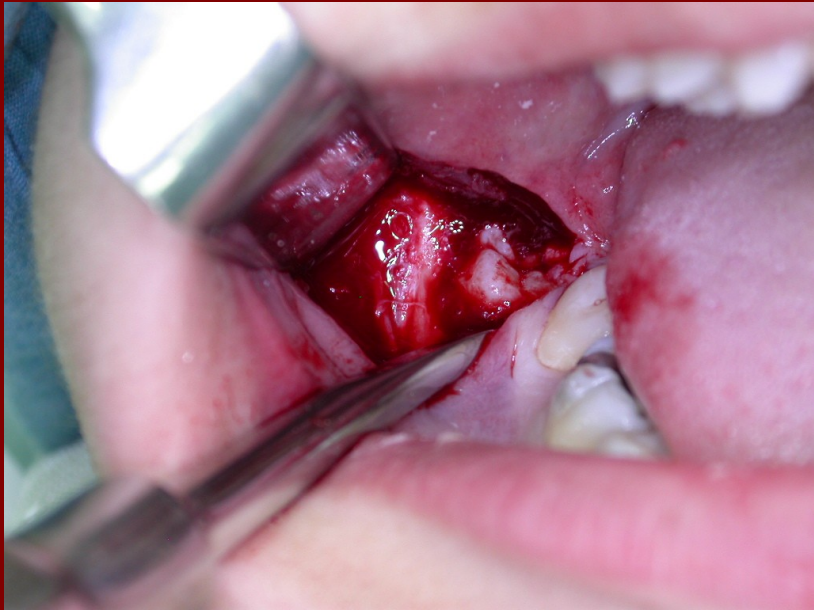


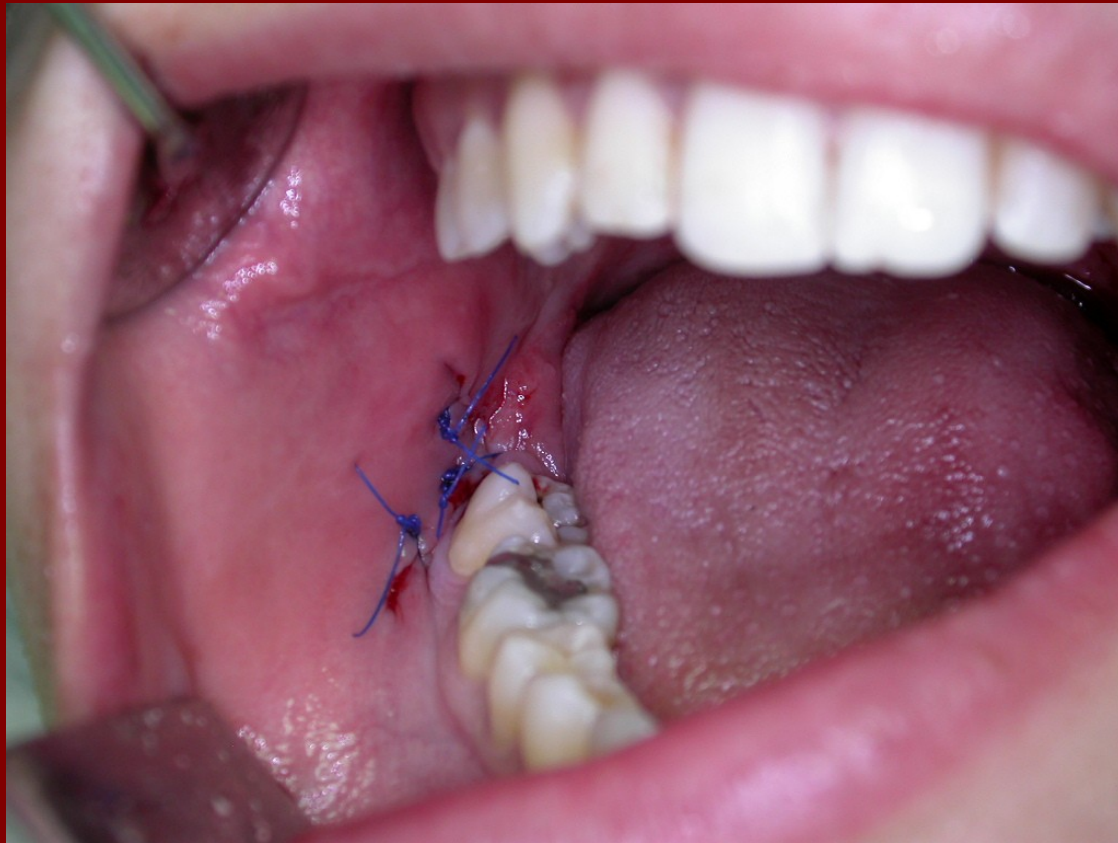(c)



(d)







The end