

# Maxillofacial Infections

Dr Hazem Al-Ahmad

B.D.S, MSc(Lon), F.D.S.R.C.S(Eng)

# Maxillofacial Infections

- Odontogenic infections are usually mild and treated by antibiotics
- A vestibular or a fascial space abscess is determined by the muscle attachment level to the point of infection perforation

# Microbiology

- concentration of the organism
- its virulence
- environmental factors
- host defense

# Steps in the management of odontogenic infections:

- Determine the severity of infection.
- Evaluate host defenses.
- Decide on the setting of care
- Treat surgically.
- Support medically
- Choose and prescribe antibiotic therapy
- Administer the antibiotic properly
- Evaluate the patient frequently.

# Severity of infection:

- Anatomic location
- Rate of progression,
- Airway compromise.

# Anatomy

- Infections spread along the "path of least resistance".

# Fascial Spaces

- Bound by the fascial layers investing muscles of the body
- contain various structures
- are *potential spaces*

# Fascial Spaces

## ■ Primary involvement spaces:

*Maxilla:* canine, buccal, infratemporal

*Mandible:* Submandibular, Sublingual, Submental

## ■ Secondary spaces:

Masseteric, pterygomandibular, superficial and deep temporal, Lateral pharyngeal, Retropharyngeal, prevertebral

# Canine Space

- Sup Origin of levator muscles
- Inf Orbicularis oris
- Ant Skin, subQ
- Post Maxilla
- Med Levator labii alaeque nasii
- Lat Zygomaticus major

# Canine Space

- Canine root has a sufficient length to erode through the alveolar bone superior to the muscles of facial expressions.
- Clinically, facial swelling that obliterates the nasolabial fold.
- Spontaneous drainage occurs just inferior to the medial canthal ligament.

# Canine Space

- Contains angular artery and vein, infraorbital foramen.
- These provide a path of communication to cavernous sinus via ophthalmic vein, leading to cavernous sinusitis and brain abscess.
- This is due to the fact that facial veins contain no valves.

# Cavernous Sinusitis

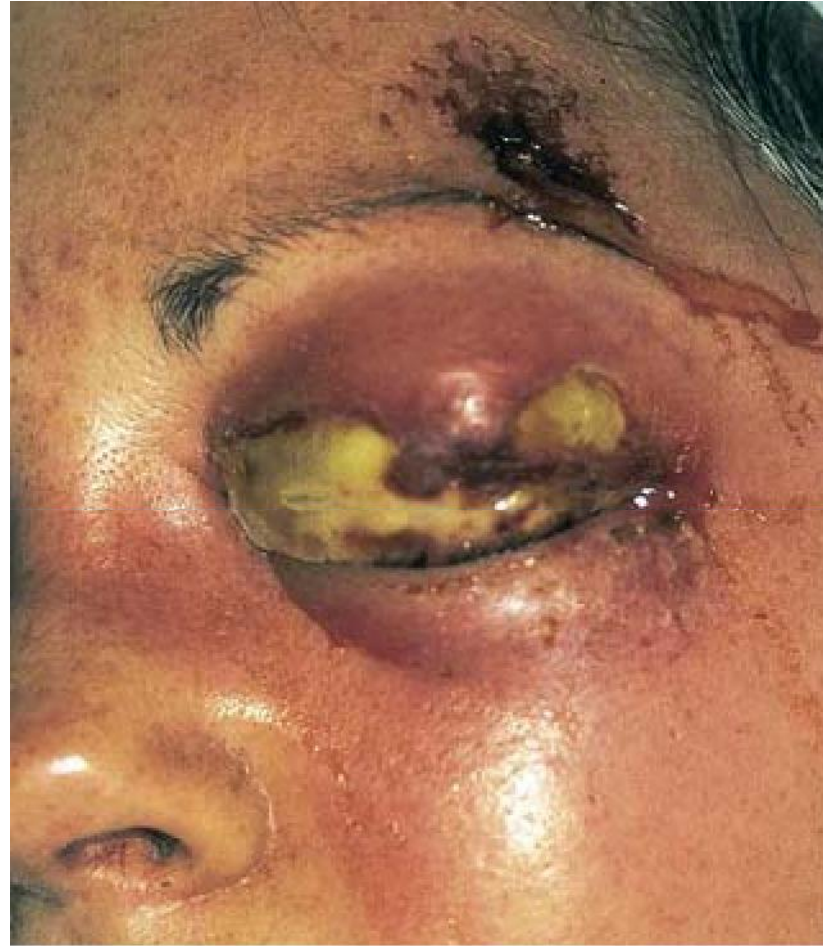- Cavernous sinus contains; CN III, IV, V1, V2, VI and internal carotid artery.
- Valveless veins of head and neck result in a "venous lake" throughout the midface and skull base.
- This will result in retrograde flow dependent on pressure gradient

# Cavernous Sinusitis

infection may spread from midface to cavernous sinus and other parts of brain via sup. and inf. ophthalmic veins, or emissary veins connecting pterygoid plexus through ovale and lacerum foramina to the cranial vault.

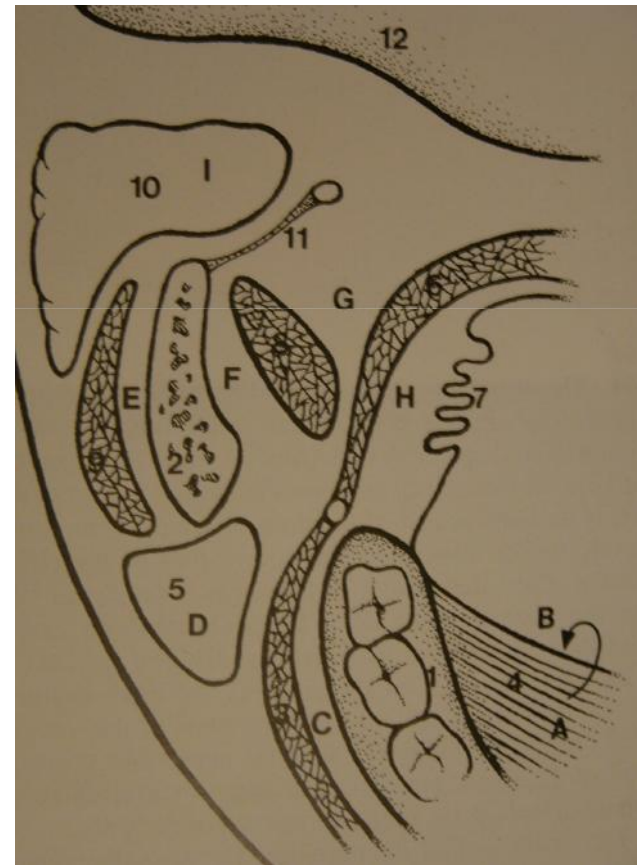
# Cavernous Sinusitis

- Earliest sign is lat gaze palsy 2o pressure on CN VI, since it is not covered by periosteum.
- Other signs include; nausea, vomiting, diplopia, visual impairment, ophthalmoplegia, photophobia, papilledema .



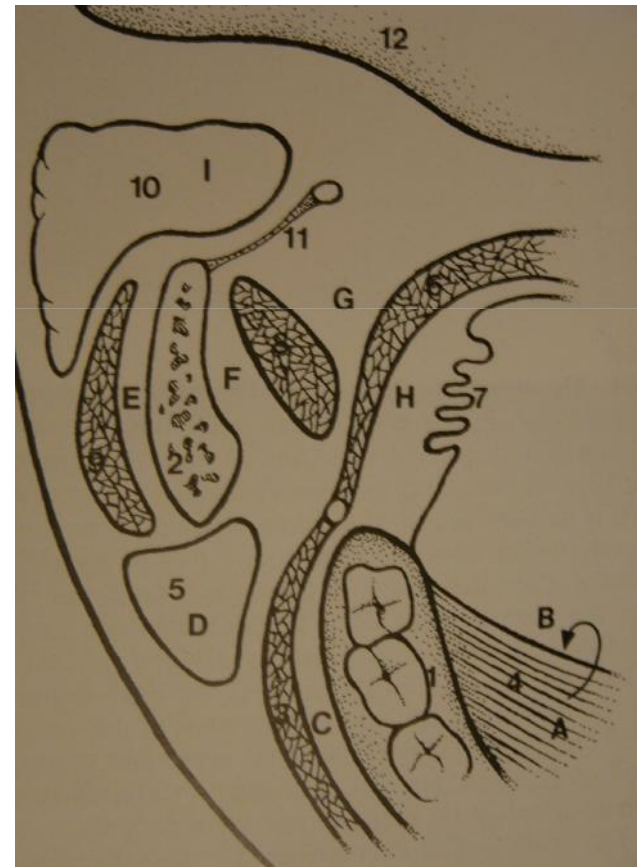
# Buccal Space

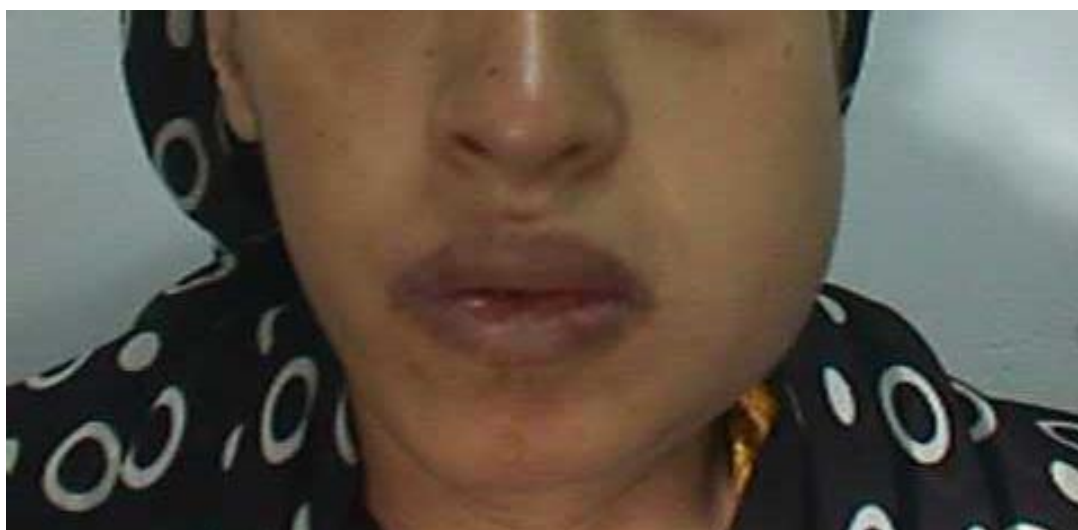- Sup Zygoma
- Inf Inferior border of mandible
- Ant Modiolus
- Post Masseter
- Med Buccinator
- Lat Skin, subQ



# Buccal Space

- Infection from maxillary or mandibular teeth (mainly maxillary)





# Buccal Space

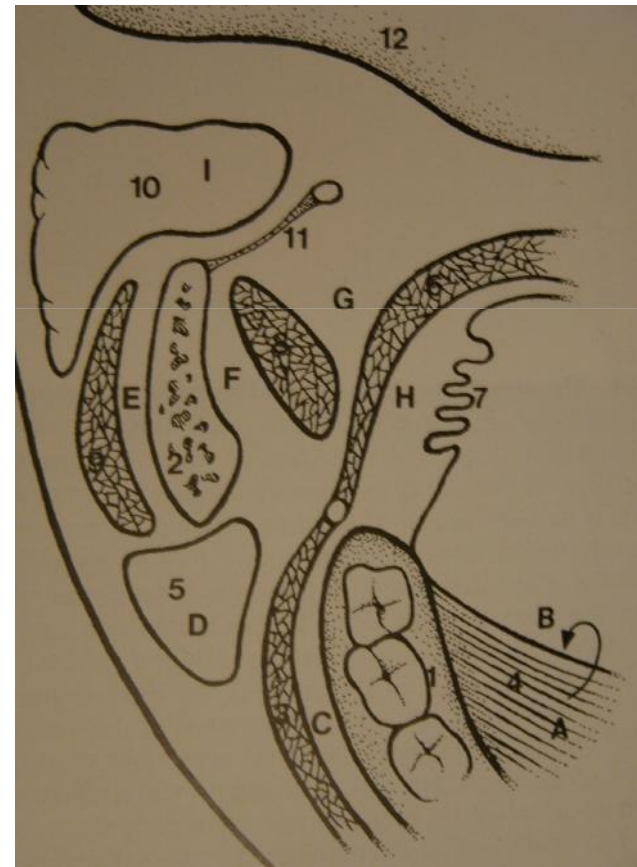
- Contains facial artery, vein, and nerve; Stenson's duct, buccal fat pad.
- The buccal fat pad acts as an impediment for spread of infection from buccal to lateral pharyngeal space.

# Buccal Space

- Clinically: swelling below zygomatic arch and above inferior border of mandible.

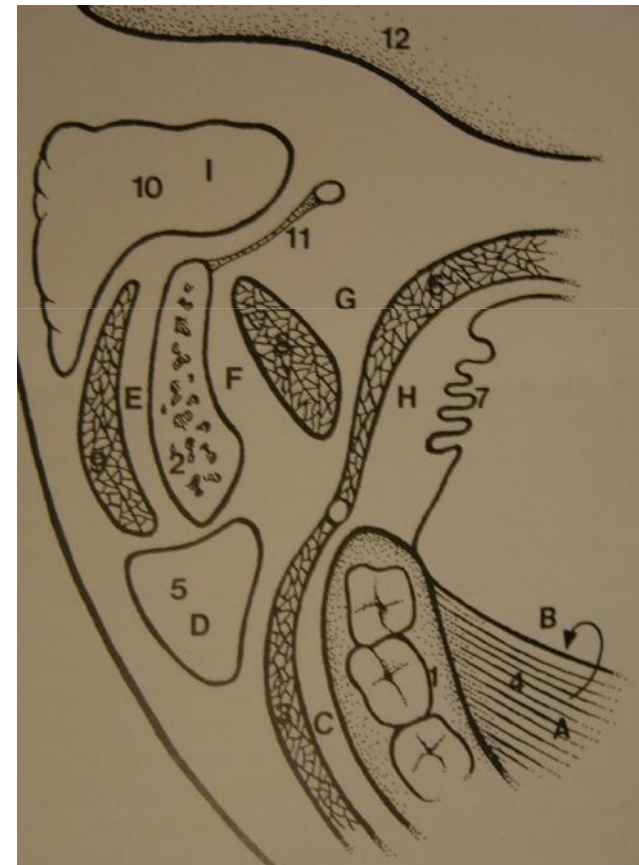
# Infratemporal Space

- lies posterior to the maxilla
- rarely infected, cause is usually from the maxillary third molar



# Infratemporal Space

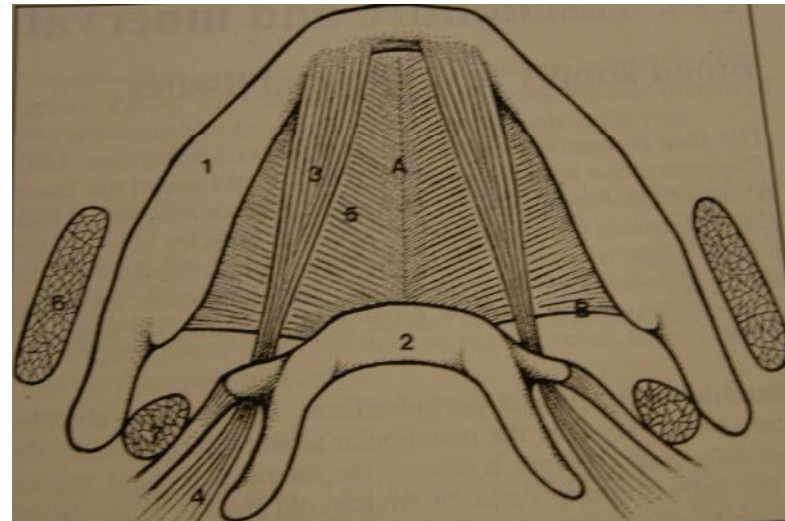
- Sup Infratemporal crest of sphenoid bone
- Inf Lateral pterygoid
- Ant Maxillary tuberosity
- Post Mandibular condyle
- Med Lateral pterygoid plate
- Lat Coronoid process



# Mandibular spaces

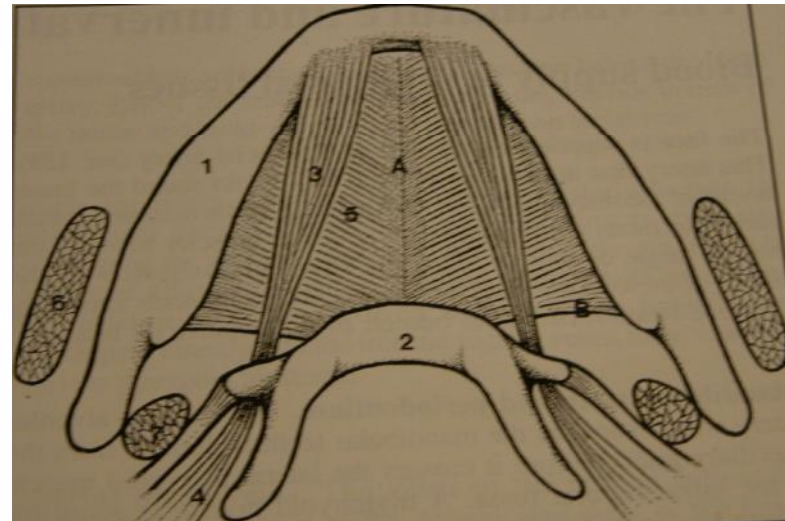
# Submental Space

- Sup Mylohyoid
- Inf Skin, subQ
- Ant Lingual mandible
- Post Hyoid
- Med Common space, no medial wall
- Lat Medial Mandible



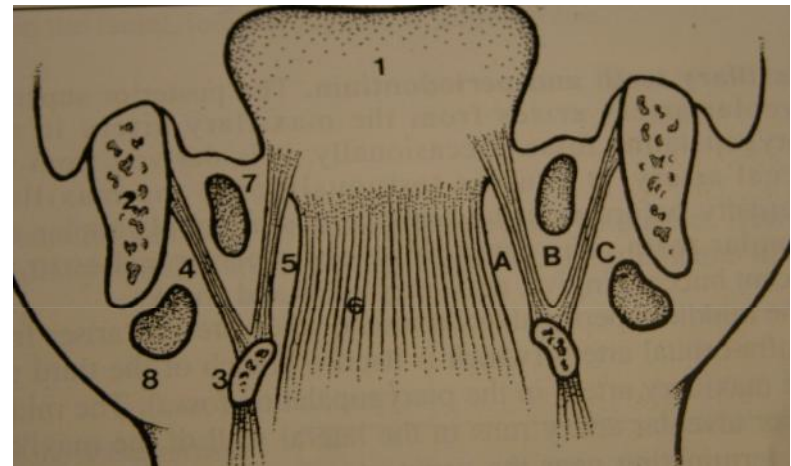
# Submental Space

- Primarily infected by mandibular incisors sufficiently long to erode through labial bone apical to the attachment of the mentalis muscle



# Submandibular Space

- Sup. Inf Mandible, Mylohyoid
- Inf. Hyoid
- Ant .Ant .Digastric
- Post. Post. Digastric
- Med. Mylohyoid, hyoglossus
- Lat. Inf. mandible, skin, subQ

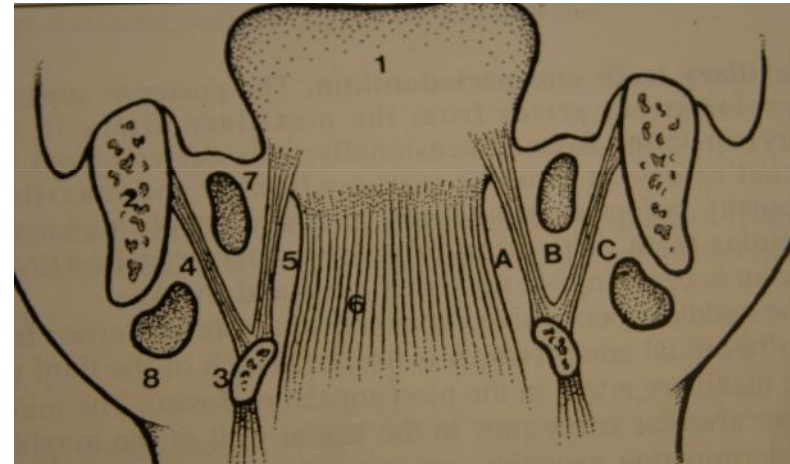


# Submandibular Space

- Contains submandibular gland, facial and lingual arteries, and lymphatics.
- most common infected space
- Lingual perforation of mandibular molars and may be involved by premolars – but mainly lower third molar
- Infection results in dysphagia, pain, swelling

# Sublingual Space

- Sup Sublingual mucosa
- Inf Mylohyoid
- Ant Lingual border mandible
- Post Hyoid
- Med Genioglossus
- Lat Medial mandible



# Sublingual Space

- Contains sublingual gland, lingual nerve, Wharton's duct, hypoglossal nerve.
- Lingual perforation of mandibular first molar and premolars mainly.
- dysphagia, pain, elevation of the floor of mouth and sup. displacement of tongue.
- Open posterior border, therefore communicates freely with the submandibular space and secondary spaces.

# Ludwig's Angina

- Infection of 5 spaces; submental, and bilateral submandibular and sublingual spaces.
- brauny edema of the spaces.
- no lymphadenopathy
- minimal inflammation of pharynx

# Ludwig's Angina

- Severe swelling, elevation of tongue, hard submandibular region.
- Trismus, drooling of saliva and difficulty with swallowing and breathing.
- Can progress rapidly and produce upper airway obstruction that can lead to death.
- Commonly streptococcal infection.

# Ludwig's Angina

- Maintenance of airway
- Manage by vigorous incision and drainage
- Aggressive antibiotic therapy

# Maxillofacial Infections II

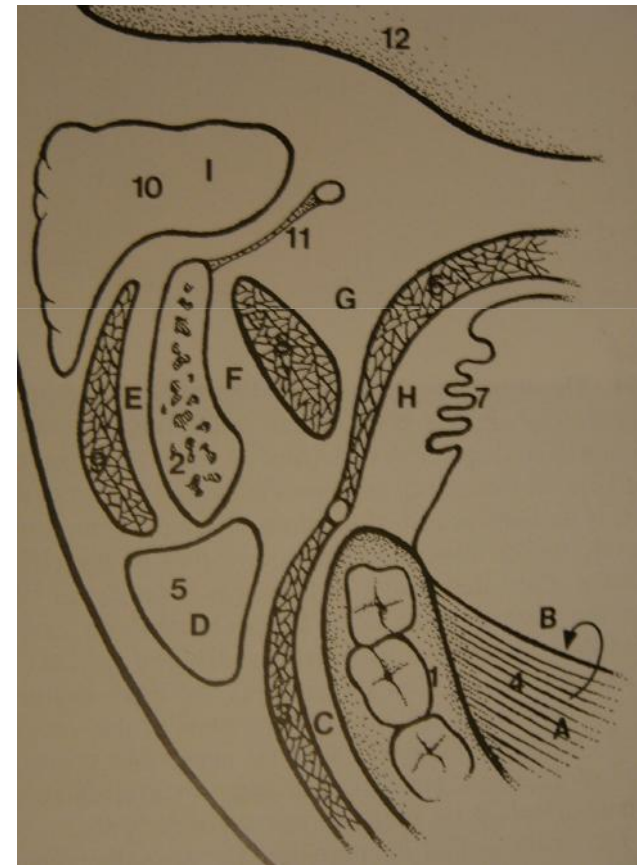
Dr Hazem Al-Ahmad

B.D.S, MSc(Lon), F.D.S.R.C.S(Eng)

# Submasseteric Space

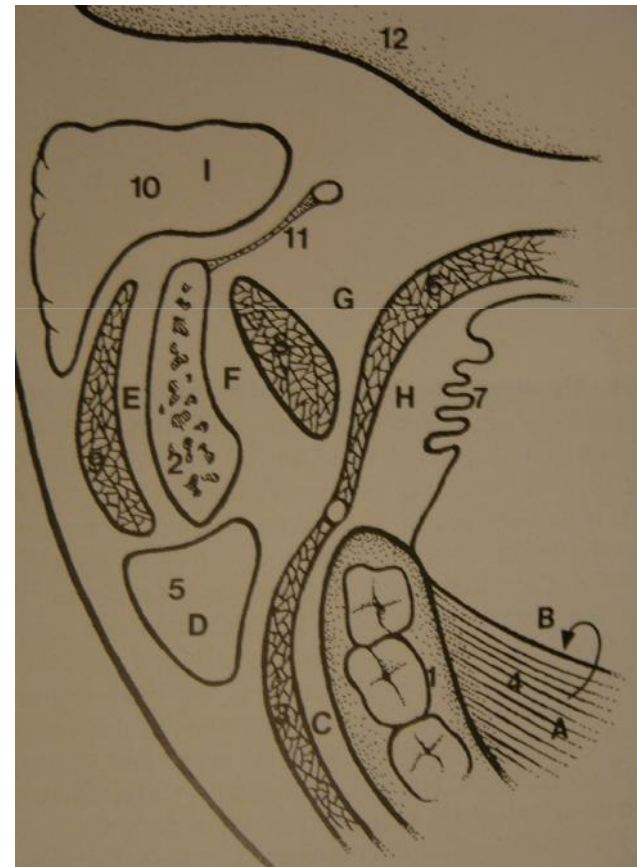
- Sup Zygomatic arch
- Inf Inferior border of mandible
- Ant Parotidomasseteric fascia
- Post Parotid
- Med Lateral mandible
- Lat Masseter

Infection would lead to trismus,  
Communicates with infratemporal fossa



# Pterygomandibular Space

- Sup Lateral pterygoid muscle
- Inf Pterygomasseteric sling
- Ant Pterygomandibular raphae
- Post Parotid
- Med Medial pterygoid
- Lat Medial ramus



# Temporal Space

- Lat Temporal Fascia
- Med Temporalis

# Cervical fascial spaces

# Lateral Pharyngeal Space

- Spread from infections pterygomandibular space
- Extends from base of skull at sphenoid bone to the hyoid bone
- Medial to the medial pterygoid muscle and lateral to superior constrictor.
- Anteriorly : pterygomandibular raphe, and posteriomediaally to prevertebral fascia

# Lateral Pharyngeal Space

- Severe trismus
- Lateral swelling of the neck and pharyngeal wall
- Complications: thrombosis of internal jugular vein, erosion of carotid artery and branches, interferences with cranial nerves IX through XII, spread to retropharyngeal space

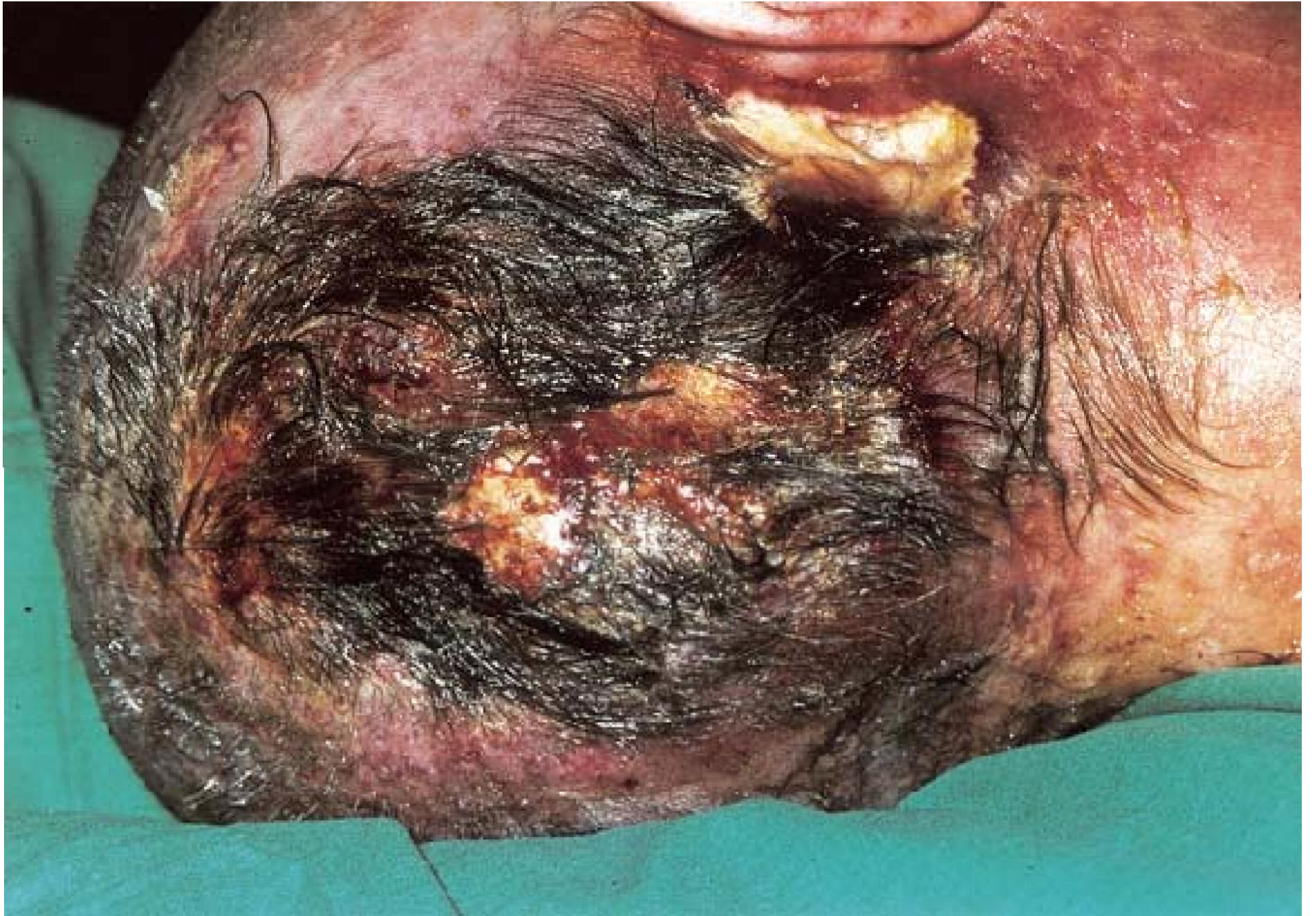# Retropharyngeal space

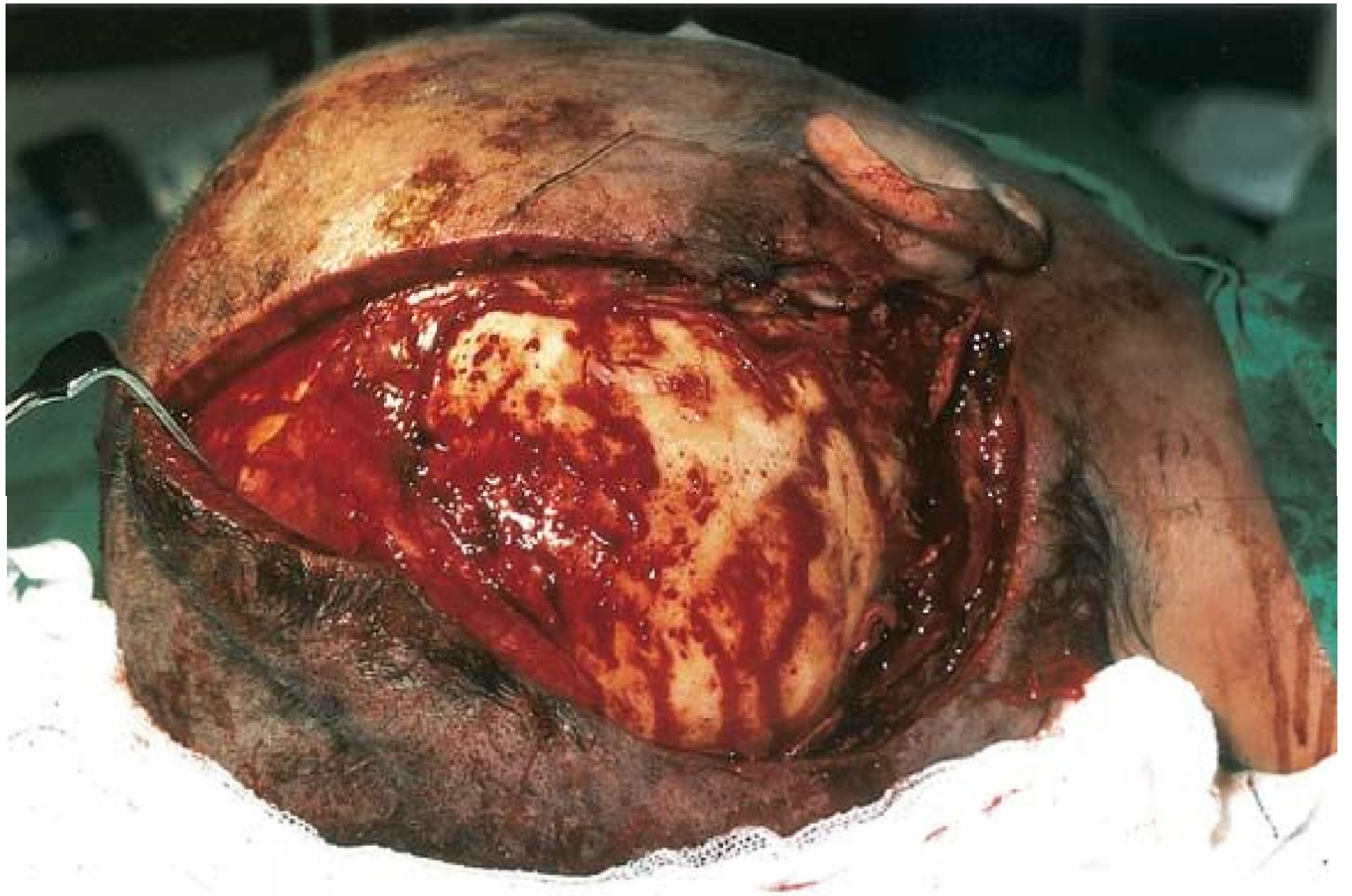
- Has few contents
- Major concern: spread to mediastinum
- Involvement of prevertebral space

# Actinomyces

# Necrotizing Fasciitis

- a polymicrobial, mixed bacterial infection of subq. tissue spreading between superficial and deep cervical fascia.
- Usually as a result of breach in the skin, and is associated with an underlying condition compromising the host immunity.





# Radiography

- Periapical
- Panoramic
- Plain film
- CT scan
- Ultrasonography

# Treatment

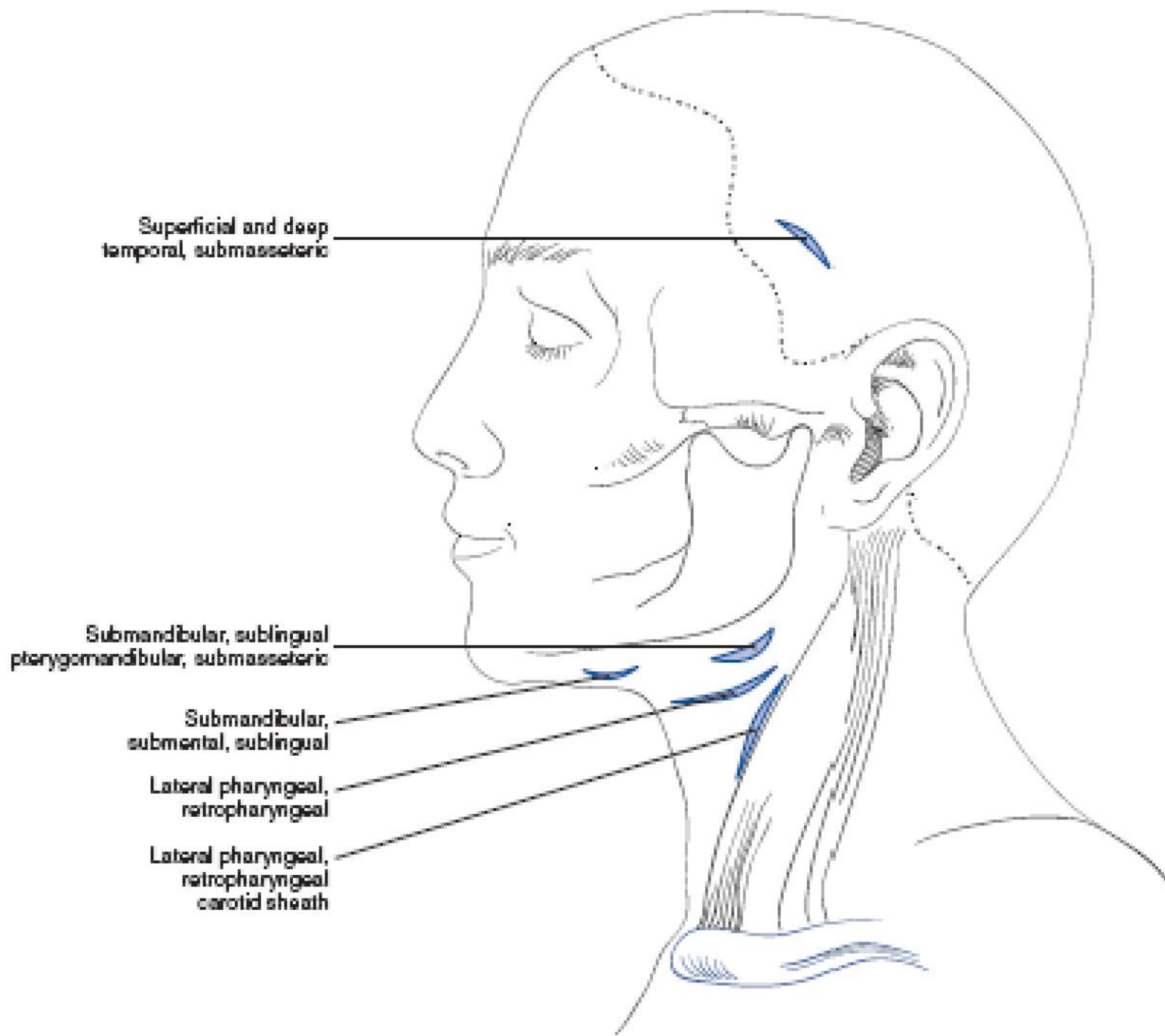
- Once diagnosis of infection is established, the principles of treatment are common.
- ABC's first,
- secure and maintain a patent, functional airway, and IV access for fluids and medications.
- In case of respiratory distress or embarrassment, intubation should be strongly considered.
- Fiberoptic intubation or surgical airway, "cric" or "trach" may be necessary if edema has distorted the anatomy

# Treatment

- remove the source of infection.
- For odontogenic infections: endodontic treatment, or extraction of the offending dentition.
- Should be done concurrently with establishment of drainage of the involved space(s).
- Antimicrobial aid
- In OMFS, treatment is incision and drainage (I&D) of the involved space and removal of the causative agent

# Incision and Drainage

- I&D technique is the same regardless of the space(s).
- Sterile preparation and draping.
- Aspiration for investigation and obtaining sample for micro-/pathologic studies.
- 1-2 cm incision through skin/mucosa.
- blunt dissection with instrument and/or finger to enter the spaces and establish drainage.
- Use shortest and most direct route to the space.
- Placement of a drain, secured to the stoma of incision with nylon, silk, or chromic suture.



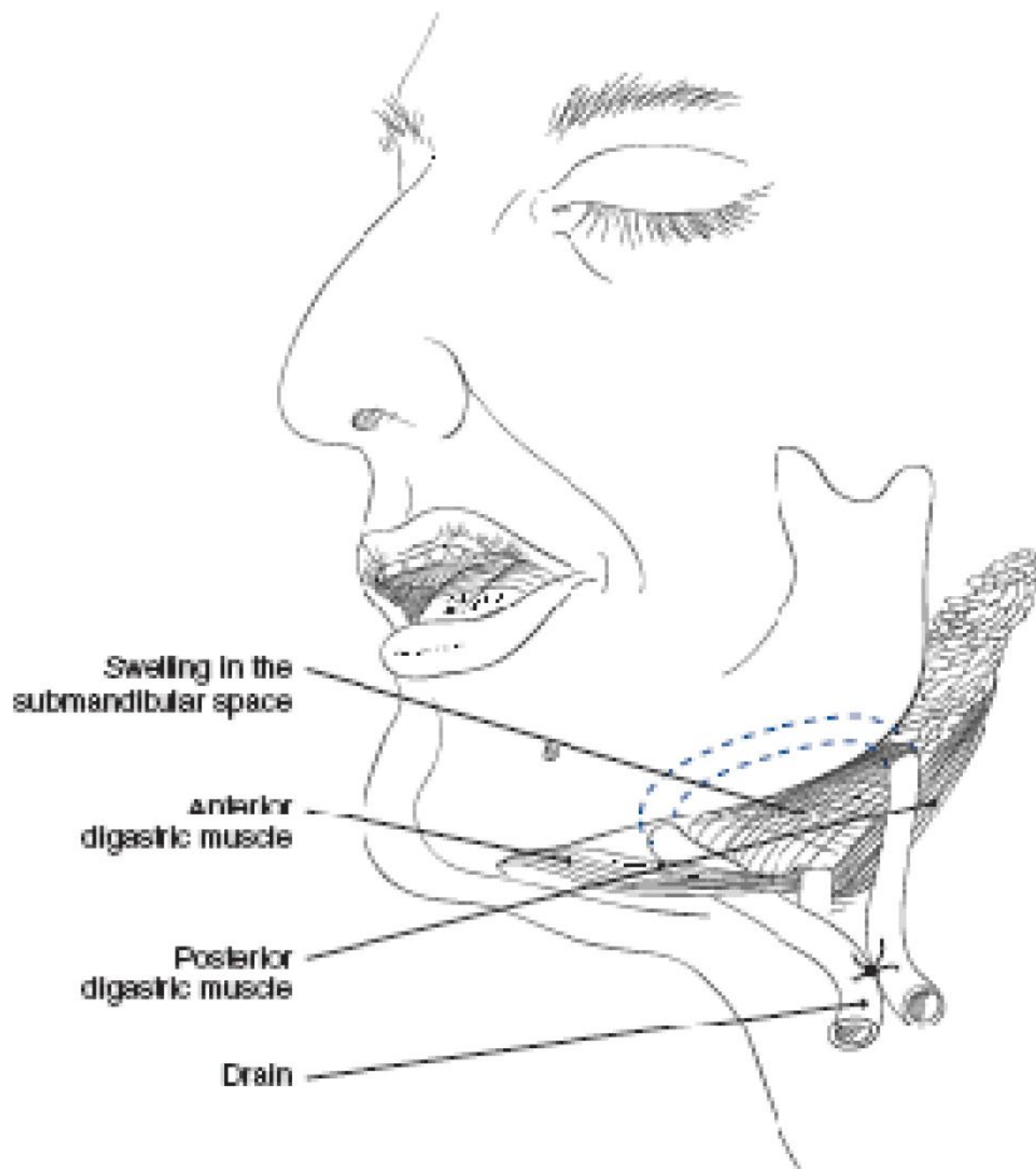
Superficial and deep  
temporal, submasseteric

Submandibular, sublingual  
pterygomandibular, submasseteric

Submandibular,  
submental, sublingual

Lateral pharyngeal,  
retropharyngeal

Lateral pharyngeal,  
retropharyngeal  
carotid sheath

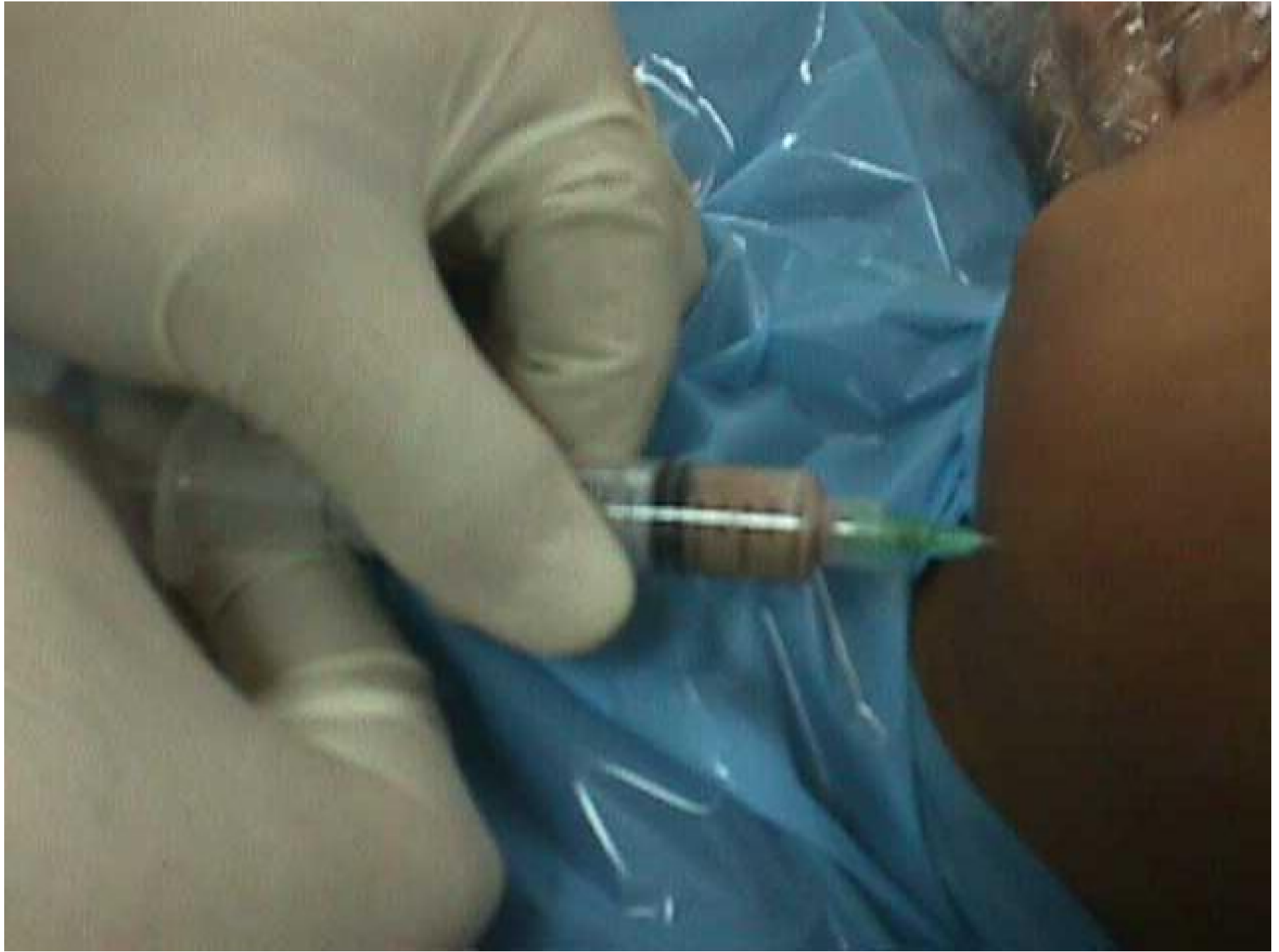

# Antimicrobial Treatment

- Adjunctive medical tx should ideally be directed at the causative organisms.
- Based on Gram Stain, cultures and sensitivity.
- Empiric tx, is initiated based on common pathogens.
- Changed based on ID, and clinical pictures.

# Antimicrobial Treatment

- Commonly used antibiotics in OMFS
- Penicillins
- Cephalosporins
- Erythromycin
- Clindamycin
- Metronidazole
- Aminoglycosides





hifa' ahmad al hensi 40y JORDAN UNIVERSITY HO

SOMATOM PLUS  
VCI  
H-SP-

-DEC-2009  
:38:07.44  
-226.0  
A 101  
I 3

/ 140  
A 240  
E 0.75  
T 0.0  
L 5.0/7.5  
PI -4/-22  
60 LO  
610

CONTRAST

W  
C

