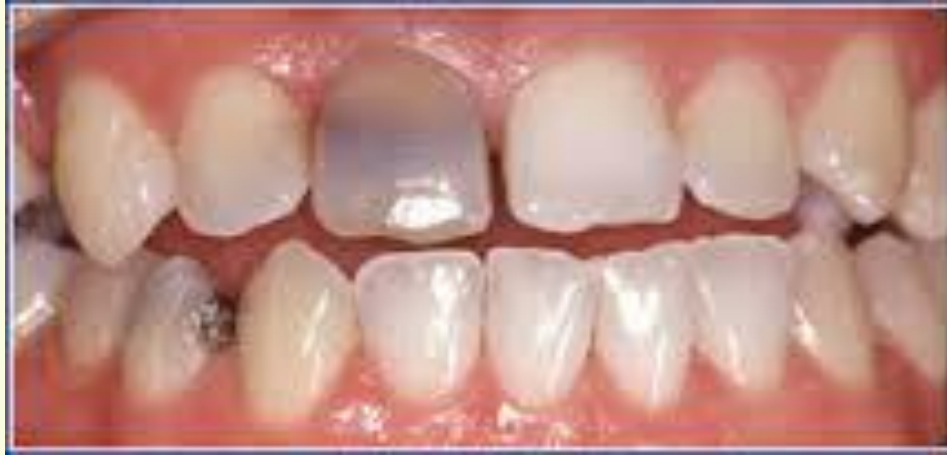

Management of discoloured teeth



Fourth year DDS students
May 2014

Ahmad El-Ma'aitha

BDS, MSc, PhD, MEndo RCSEd



Outline:

I- Tooth shade determinants.

II- Aetiology of discolouration.

III- Other treatment options for discoloured teeth

IV- Bleaching:

a) History

b) Material

c) Mechanism of action


d) Techniques

e) Potential adverse effects



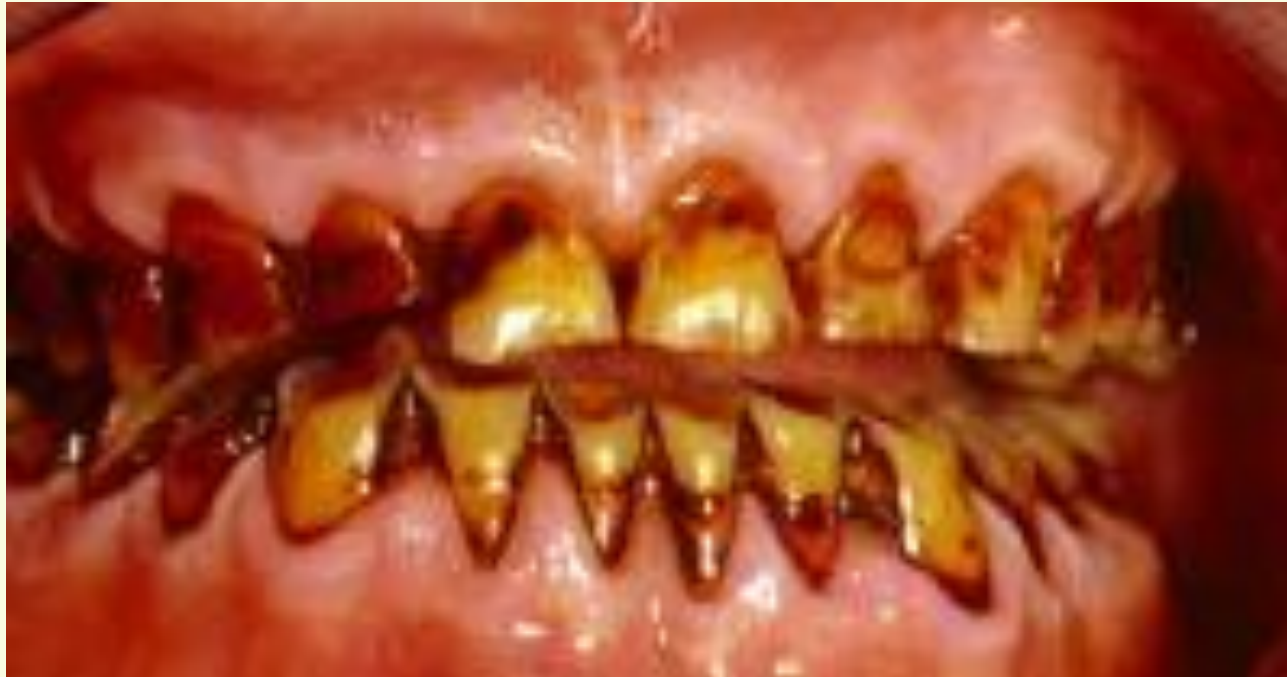I- Shade determinants:

The shade of a tooth depends on the light transmission properties of its constituents (enamel, dentine and pulp). Structural changes in these tissues either during tooth development or post-eruption results in changes in their reflective/ absorptive properties and therefore discolouration.





Discoloured teeth can be a physical handicap that impacts on a person's self-image, confidence, physical attractiveness and even employability!





II- Aetiology of tooth discolouration:

a) Extrinsic discolouration:

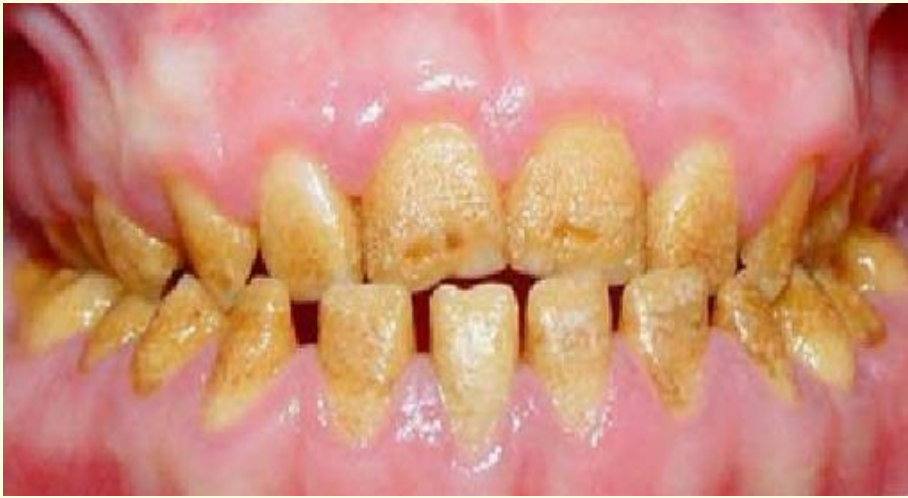- Plaque and Calculus
- Chromogenic bacteria
- Dietary origin (tea, coffee, coloured food... etc)
- Smoking
- Chlorhexidine MW



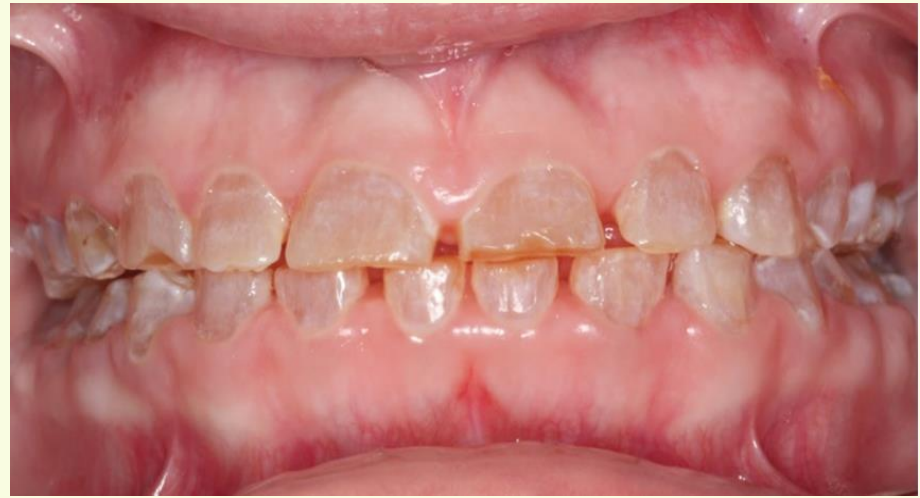II- Aetiology of tooth discolouration:

b) Intrinsic discolouration:

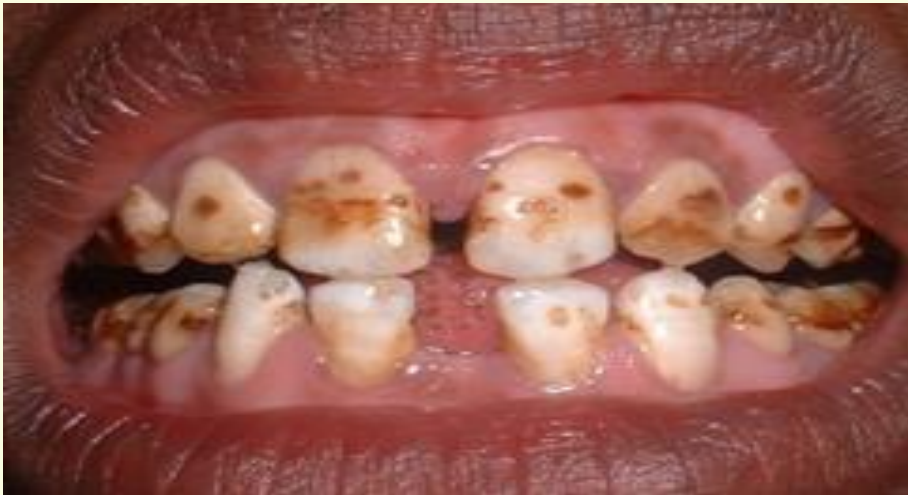- Amelogenesis and dentinogenesis imperfecta
- Tetracycline staining
- Fluorosis
- Trauma
- Ageing
- Restorative materials
- Caries
- Toothwear
- Systemic disease: Haematological, porphyria, alkaptonuria



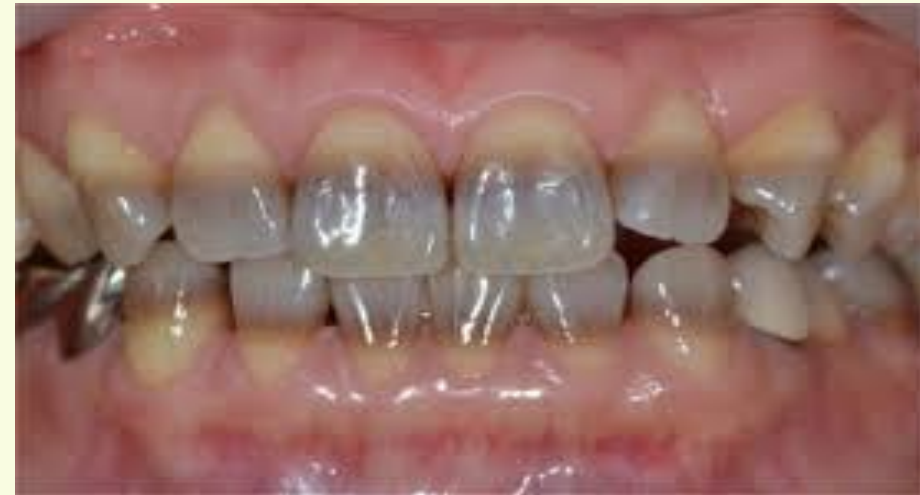Amelogenesis imperfecta



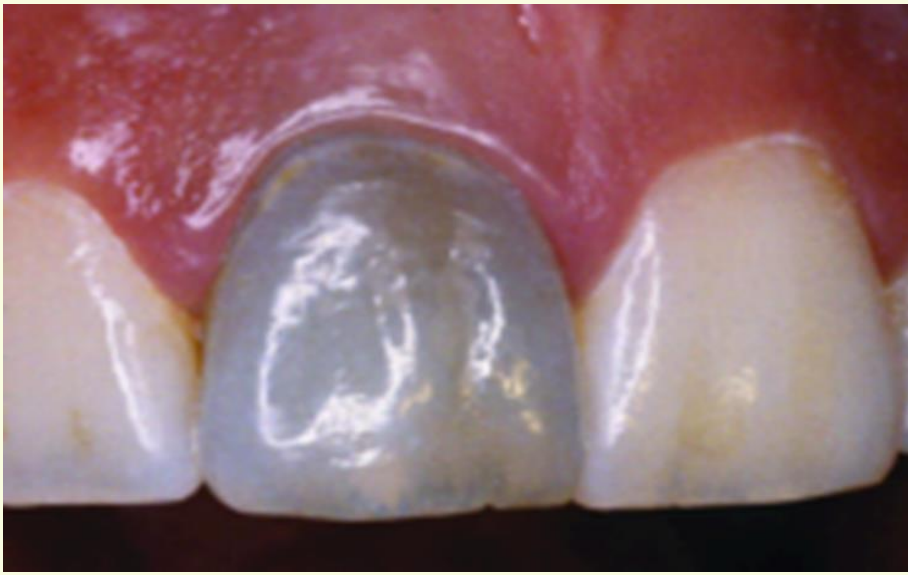Dentinogenesis imperfecta



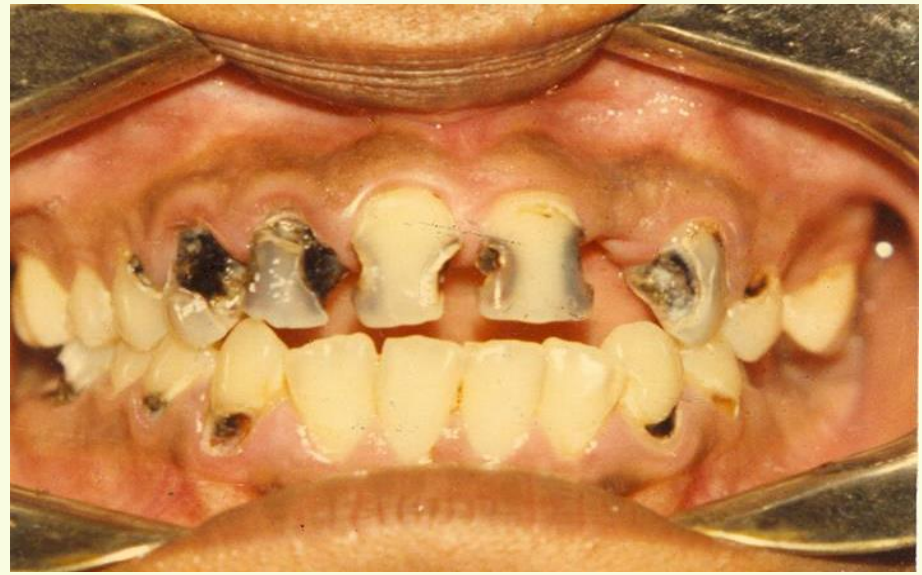Fluorosis



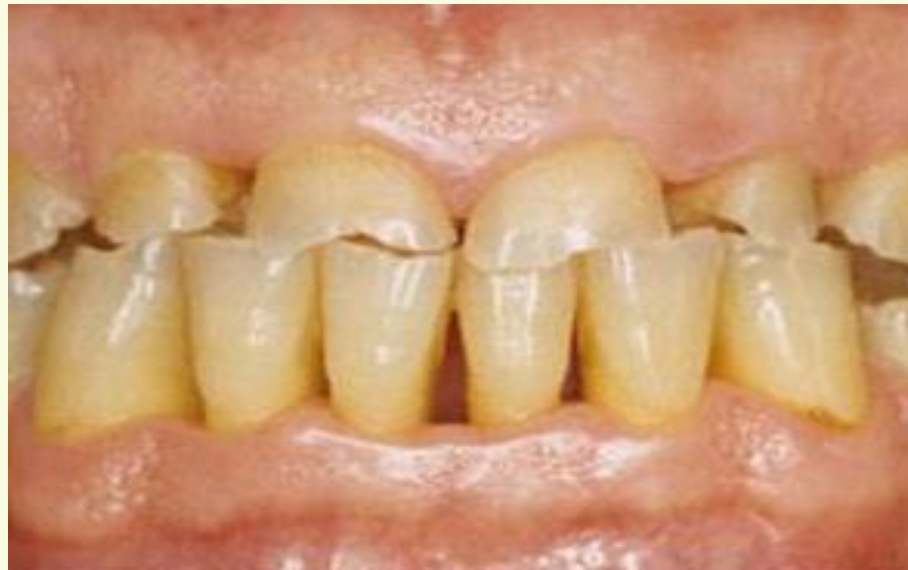Tetracycline staining



Trauma



Caries



Tooth wear



III- Treatment options for discoloured teeth:

- 1- Scaling and polishing: *only removes some extrinsic stain*
- 2- Bleaching: *simple and conservative option*
- 3- Micro-abrasion
- 4- Direct composite restoration
- 5- Indirect veneers/ crowns: *destructive and expensive!*



IV- Bleaching:

Definition: the lightening of the colour of a tooth, or teeth, through the application of a chemical agent.

The most requested procedure in cosmetic dentistry today.

More than 100 million Americans whiten their teeth one way or another; spending an estimated \$15 billion in 2010.



IV.a- History of bleaching:

- First report of bleaching for non-vital teeth was in 1848, while that of vital teeth was in 1868.
- Chlorinated lime was recommended for the whitening of non-vital teeth. Later, oxalic acid, chlorine compounds and solutions, sodium peroxide, sodium hypochlorite or mixtures of hydrogen peroxide (H_2O_2) were used.
- Some authors proposed using light, heat or electric current to accelerate the bleaching reaction.



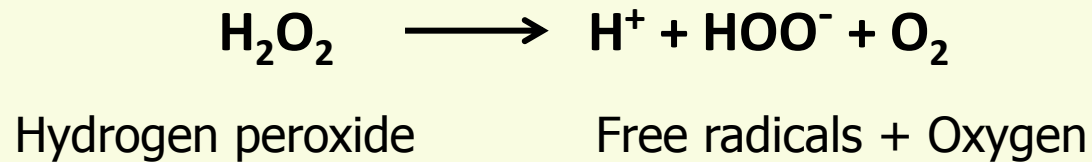
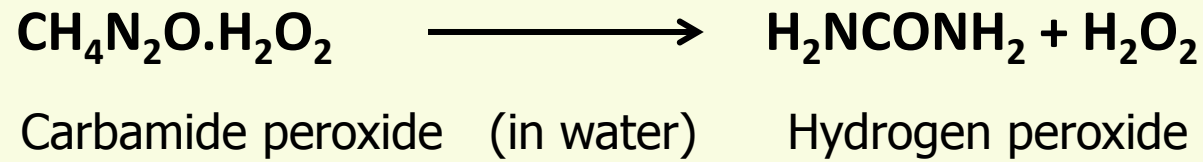
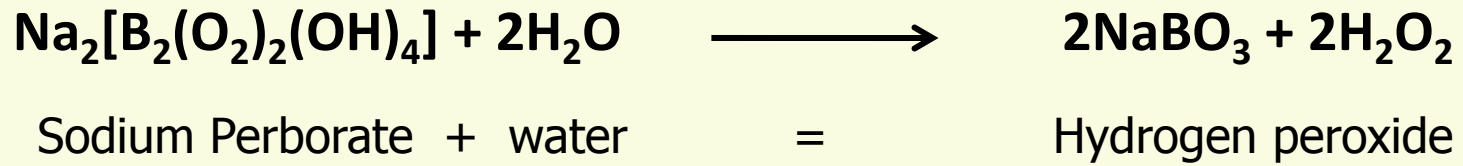
IV.b- Material:

- The active agent in any bleaching material is hydrogen peroxide (H_2O_2), which may be applied directly, or produced in a chemical reaction from either sodium perborate or carbamide peroxide with water.



IV.c- Mechanism of action:

- Hydrogen peroxide is a strong oxidizing agent that attacks the long-chained, dark-colored chromophore molecules and split them into smaller, less colored, and more diffusible molecules.
- Carbamide peroxide also yields urea that theoretically can be further decomposed to carbon dioxide and ammonia. The high pH of ammonia facilitates the bleaching procedure.



Intrinsic

Amenable to bleaching treatment? ✓ or ✗

✓	Alkaptonuria
✓	Congenital erythropoietic prohyria
✗	Amelogenesis imperfecta
✗	Dentinogenesis imperfecta
✓	Tetracycline staining
✓	Fluorosis
✗	Enamel hyoplasia
✓	Pulpal haemorrhagic products
✗	Root resportion
✓	Ageing

Extrinsic
Non-metallic

- ✓ Dietary components
- ✓ Beverages
- ✓ Tobacco – smokeless or traditional
- ✓ Mouthwashes
- ✓ Medicaments

Extrinsic
Metallic

- ✓ Copper
- ✓ Iron
- ✓ Potassium permanganate
- ✓ Silver nitrate salt
- ✓ Stannous fluoride

Internalised

- ✓ As per extrinsic



IV.d- Techniques:

Bleaching techniques are classified as to whether they involve vital or non-vital teeth into:

- 1- vital (external) bleaching
- 2- non-vital (internal) bleaching

Both clinical techniques rely upon the action of hydrogen peroxide.



IV.d.1- Vital bleaching

- Usually involves more than one tooth.
- Causes of tooth discolouration would include ageing, fluorosis, Tetracycline-staining... etc.
- Can be performed at home or in-office
- 3 major types:
 - i. In-office bleaching
 - ii. At-home bleaching
 - iii. Over-the-counter products.



i- In-office bleaching:

- Bleaching agent applied to the labial/buccal surfaces of teeth and a catalyst of some sort (light, lazer or heat source) is used to activate the bleaching process.
- Typically a 1-hour procedure using 20-40% hydrogen peroxide.



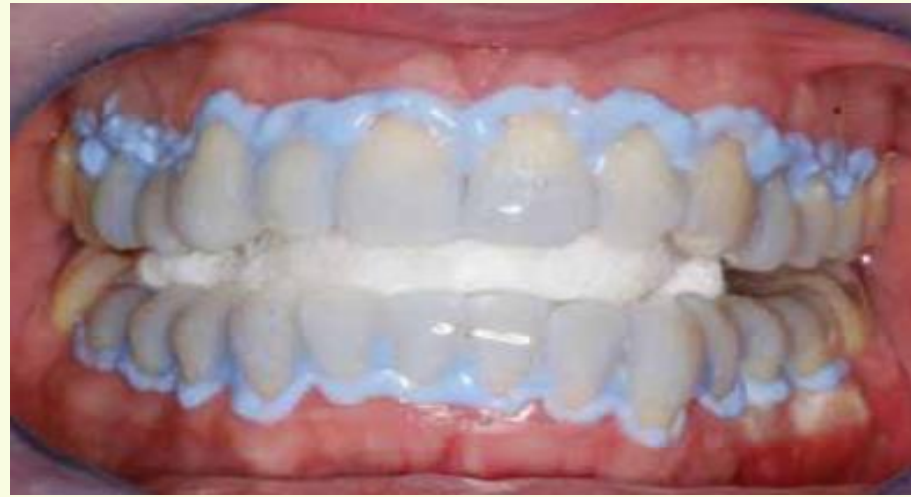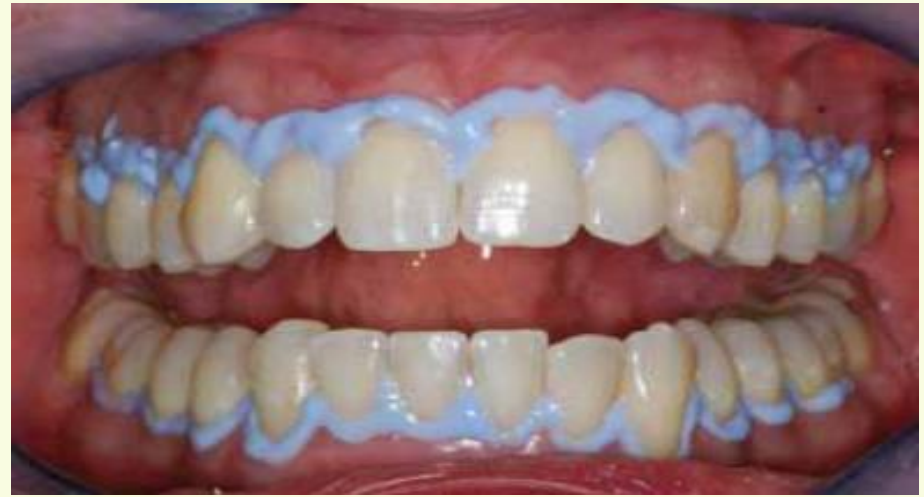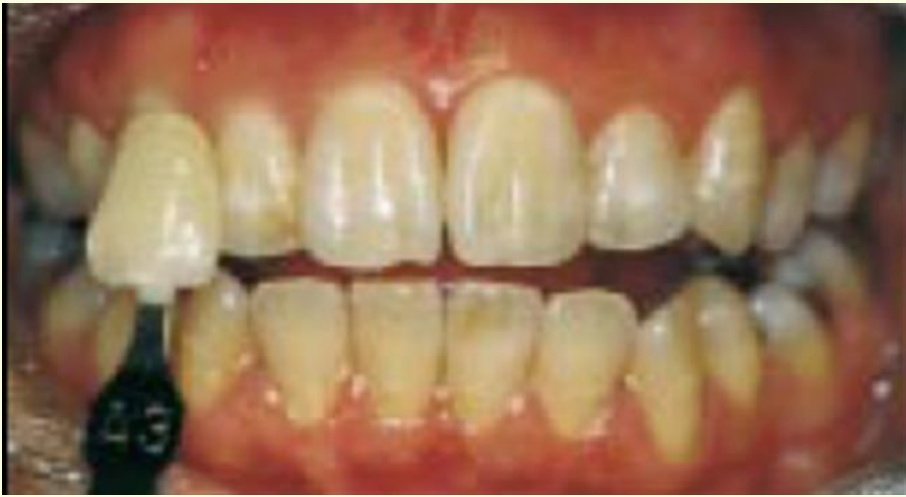i- In-office bleaching:

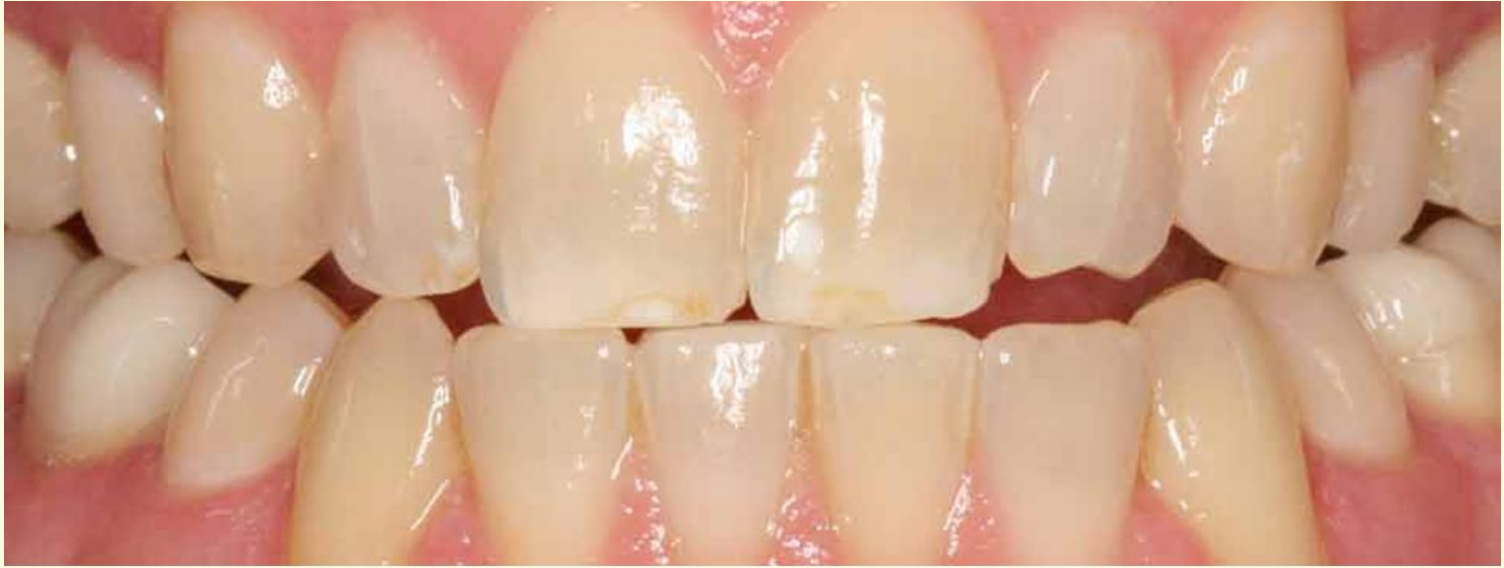Clinical steps:

- 1- Thorough examination: check for caries, cracks, defective restorations, radiographs etc.
- 2- Discussion of treatment options + patient education re: the effect of oral hygiene, diet and smoking.
- 3- Pre-operative shade registration (photographs).
- 4- Thorough scaling and prophylaxis to eliminate surface stains.
- 5- Isolation of teeth + gingival protection (resin barrier to cover 3-4mm apically from the gingival margin) + cheek and lip retractor.

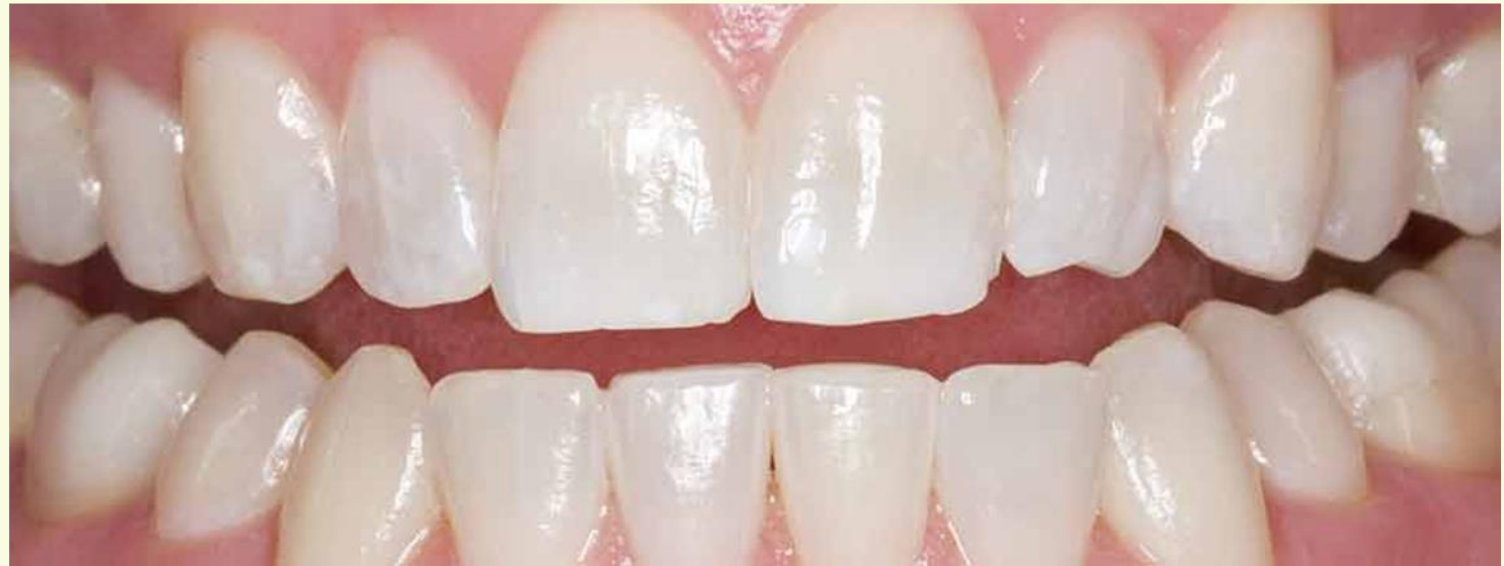

- 6- Hydrogen peroxide gel (supplied in a dual barrel mixing syringe) applied to teeth in a thickness of between 0.5mm and 1.0mm
- 7- A light is used to activate the whitening gel.
- 8- The whitening gel is left on for 15 minutes and then rinsed off with a vigorous amount of water.
- 9- Any excess gel should be removed using gauze, working from the cervical to the incisal edge.
- 10- The procedure can be repeated depending on the severity of the discolouration until the desired shade is reached

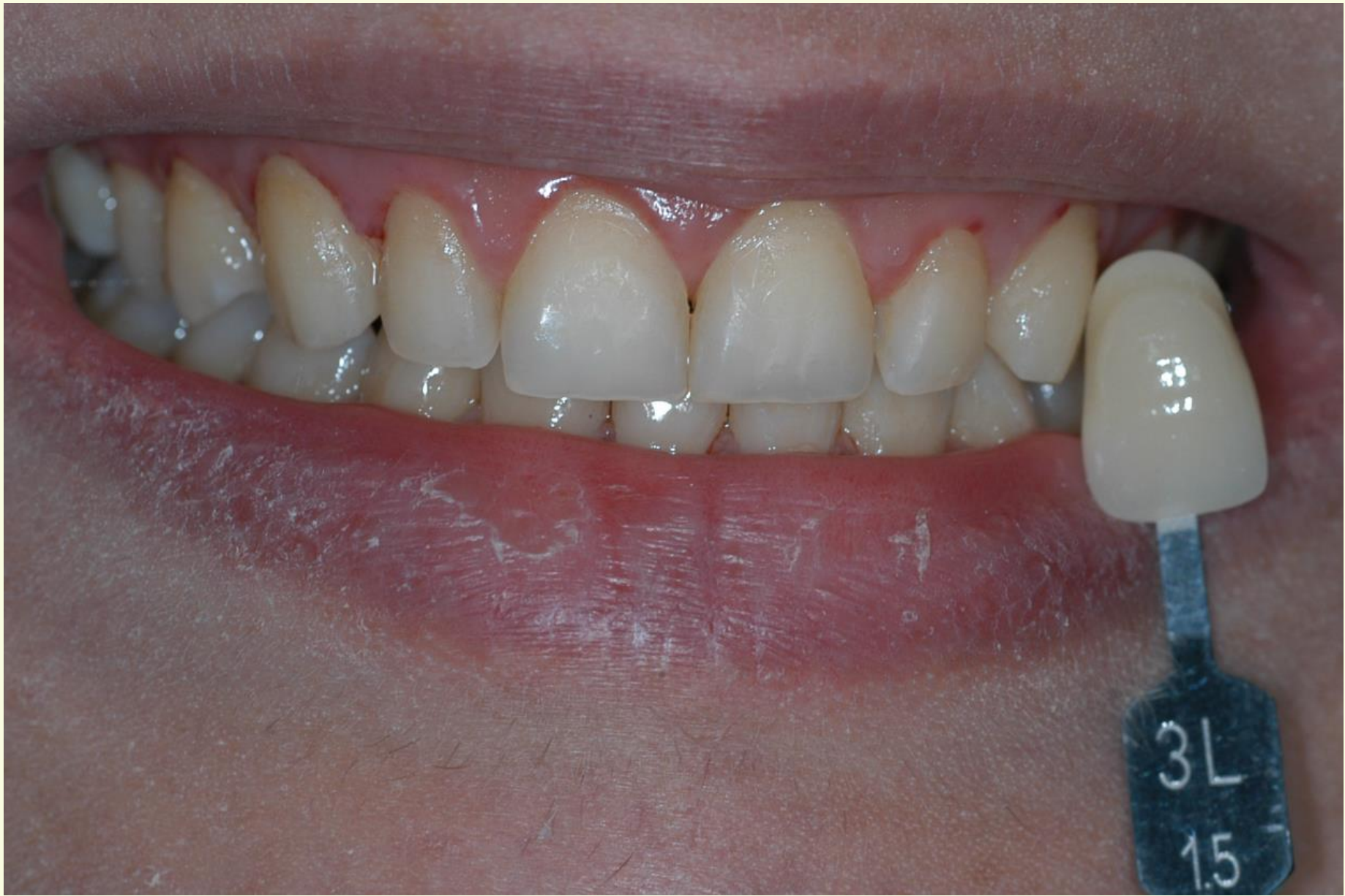


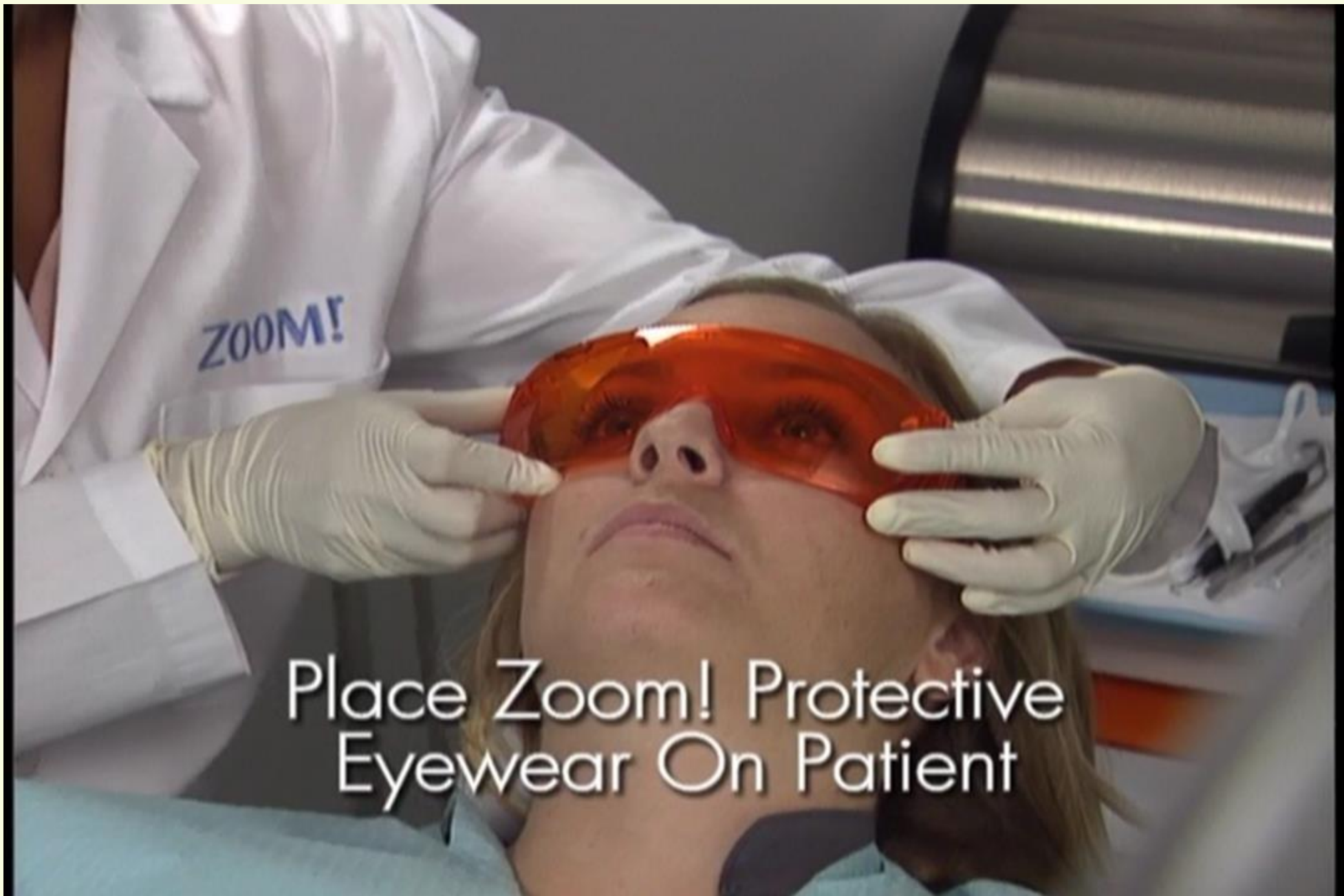
Before

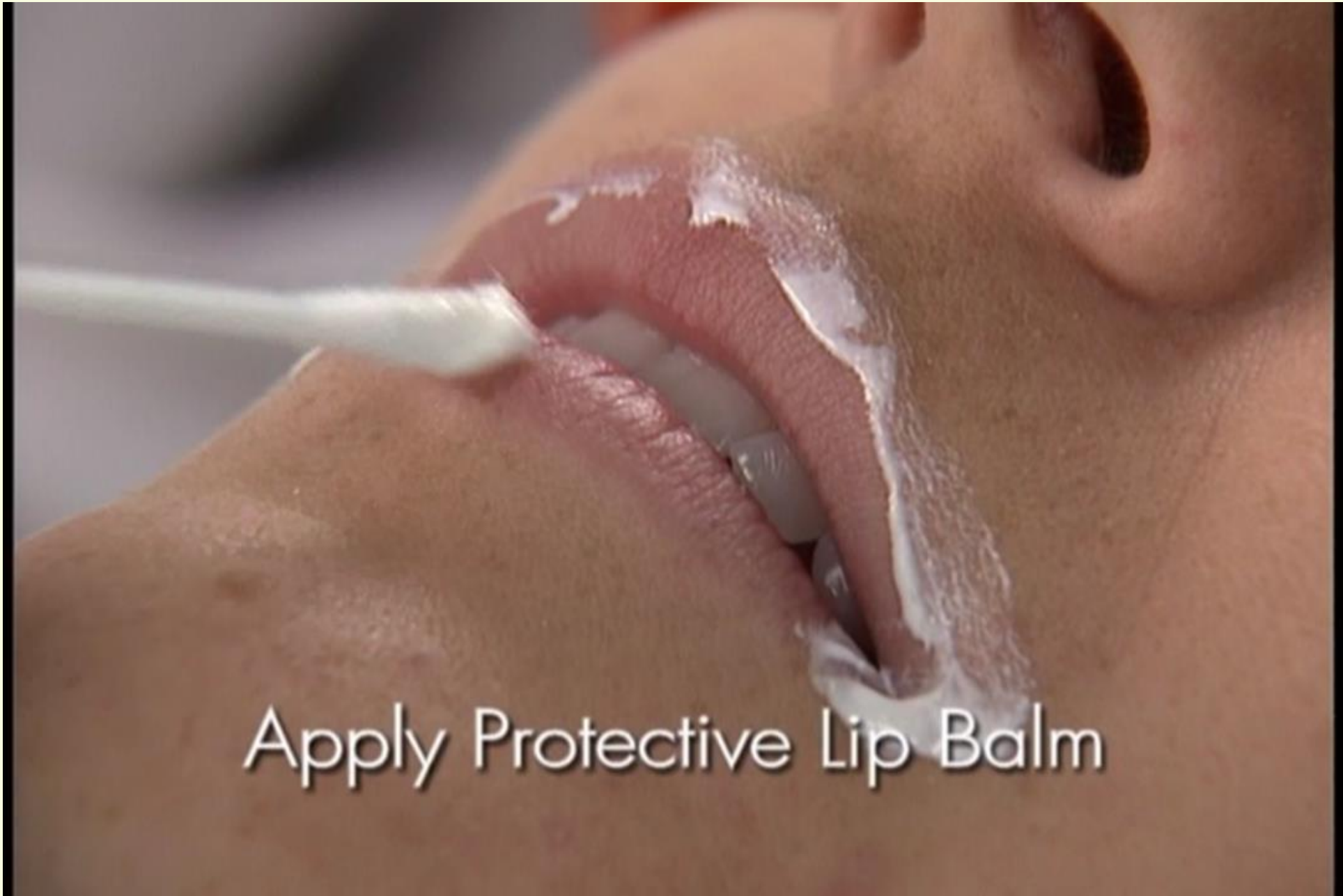

After



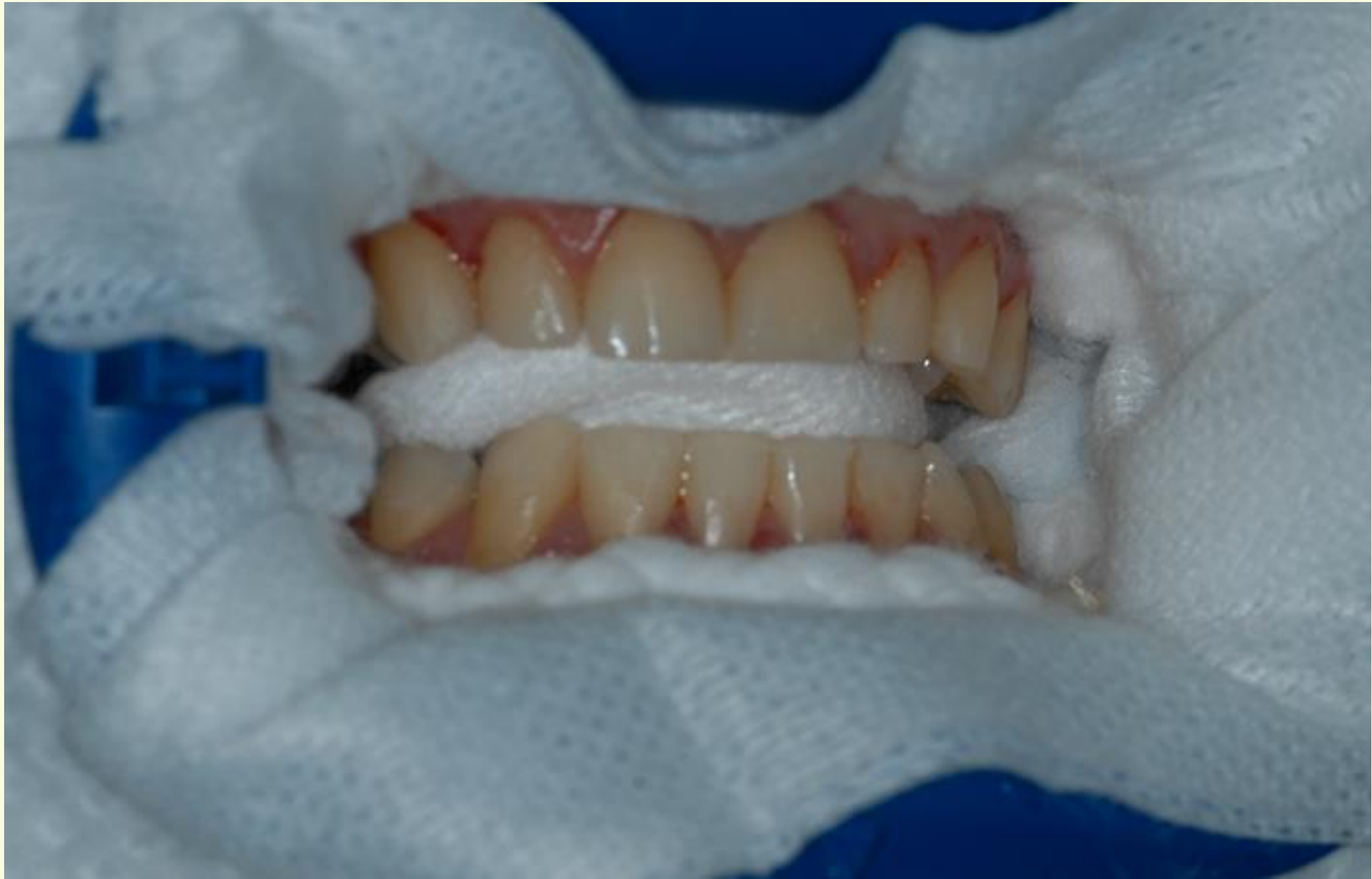

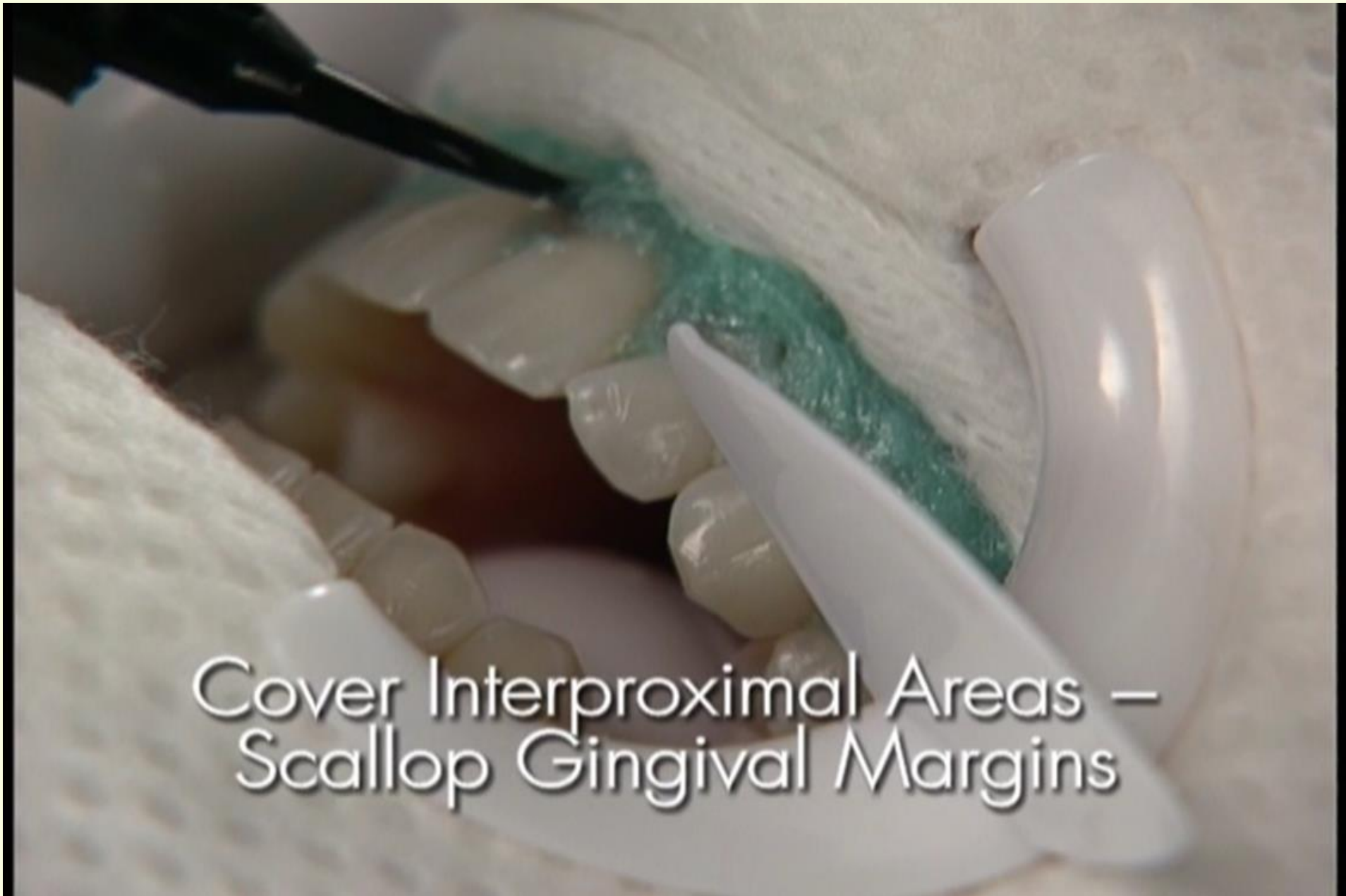Place Zoom! Protective Eyewear On Patient



Apply Protective Lip Balm

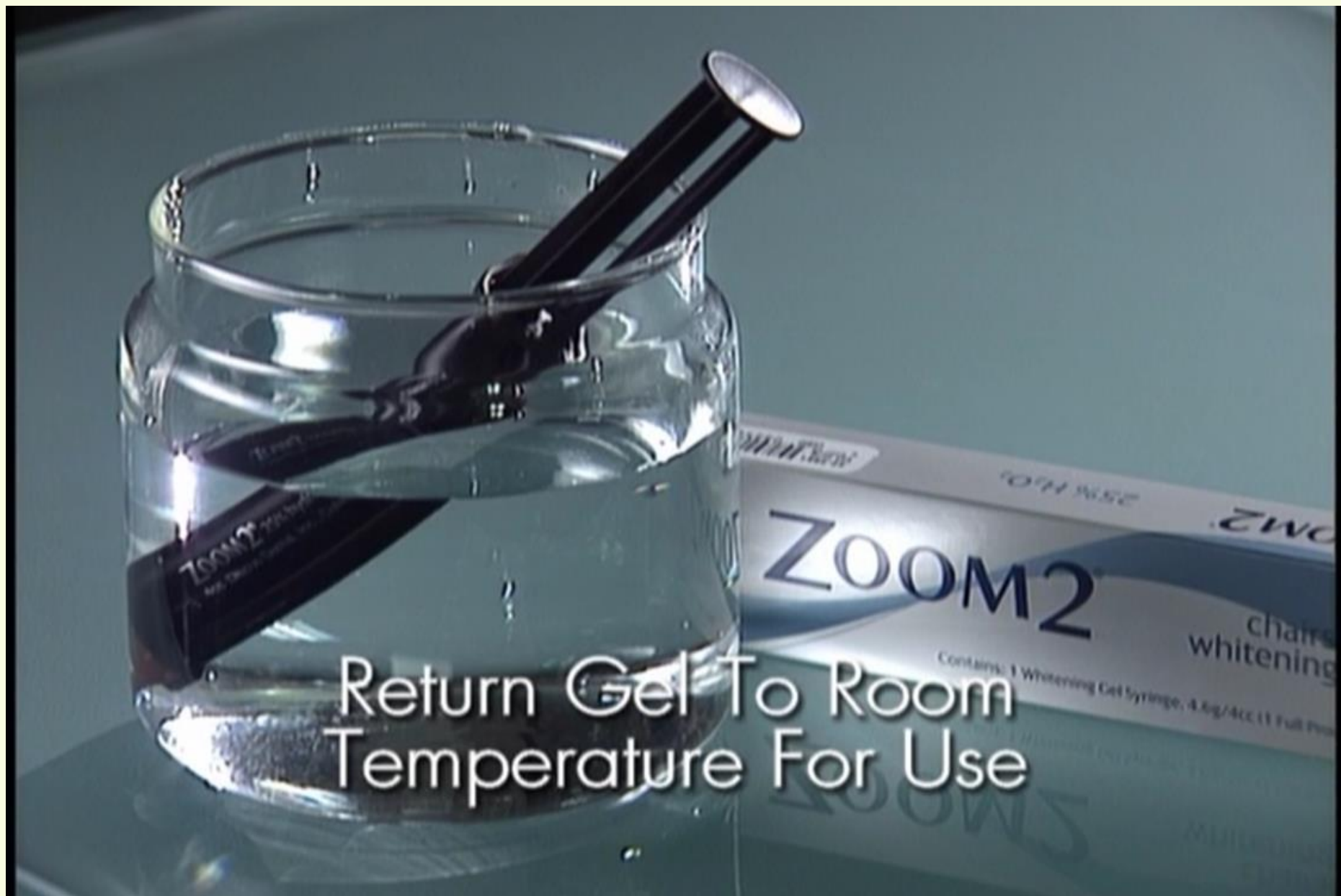




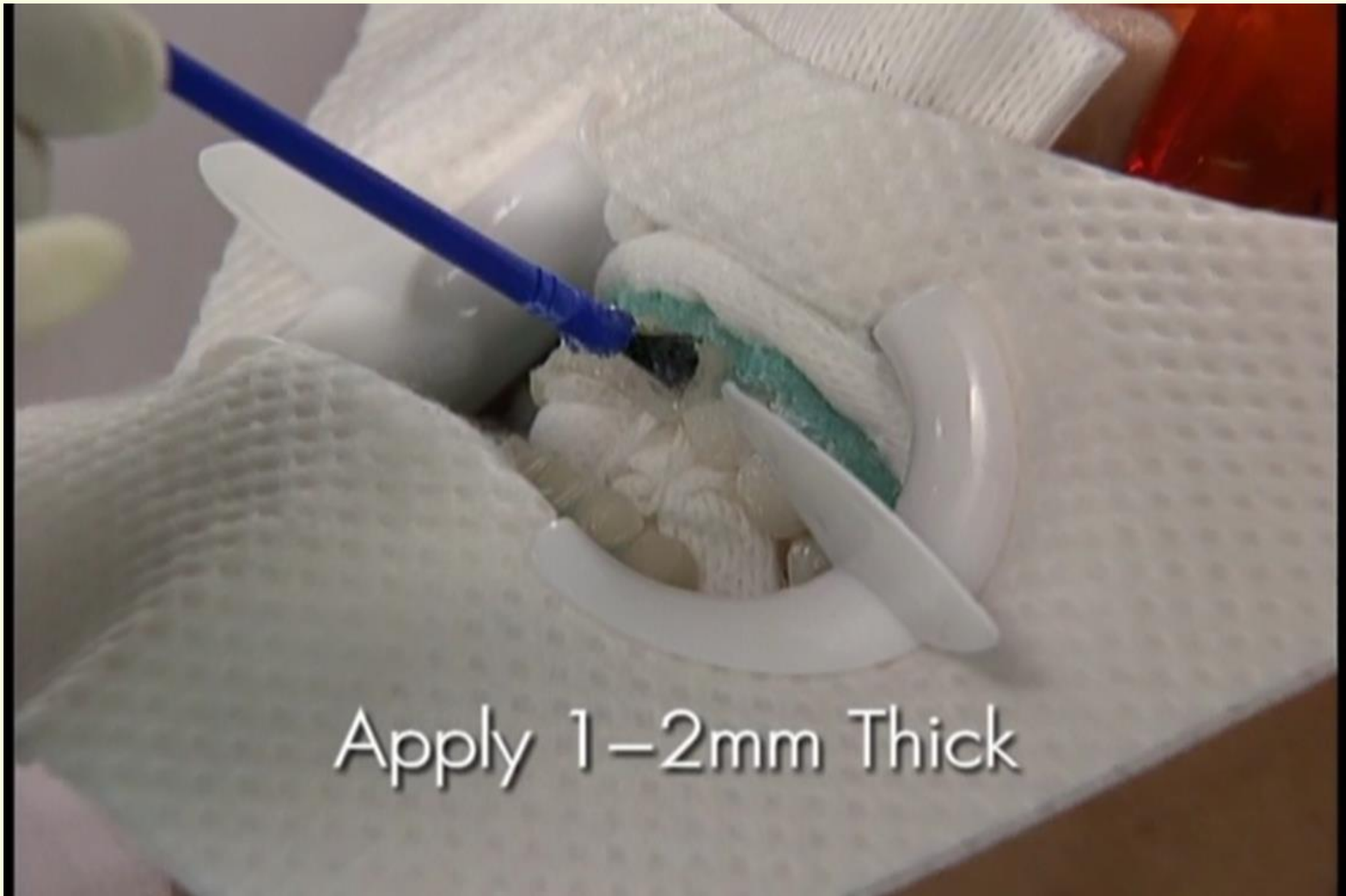

Cover Interproximal Areas –
Scallop Gingival Margins



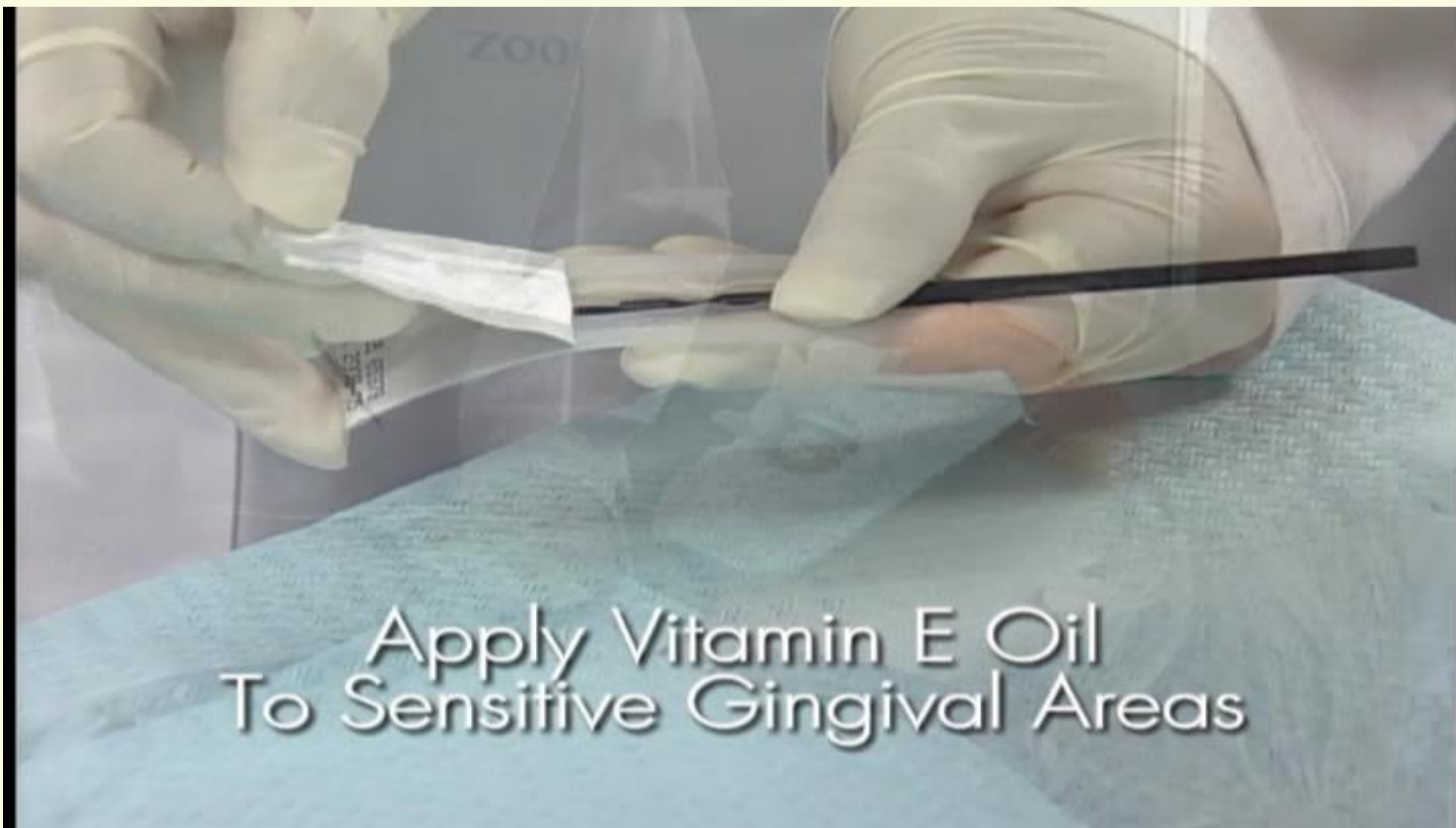


Return Gel To Room
Temperature For Use



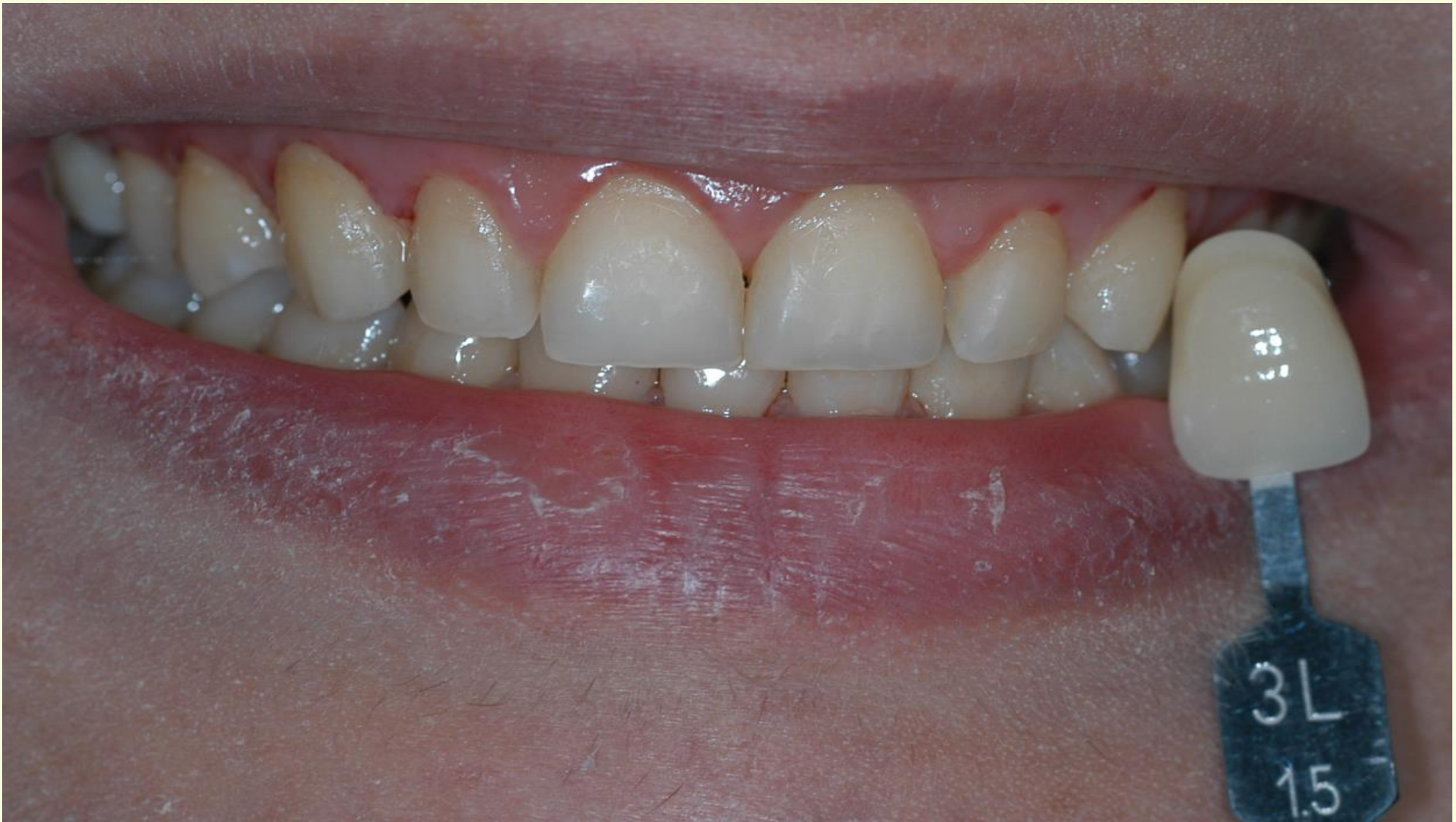Apply 1-2mm Thick

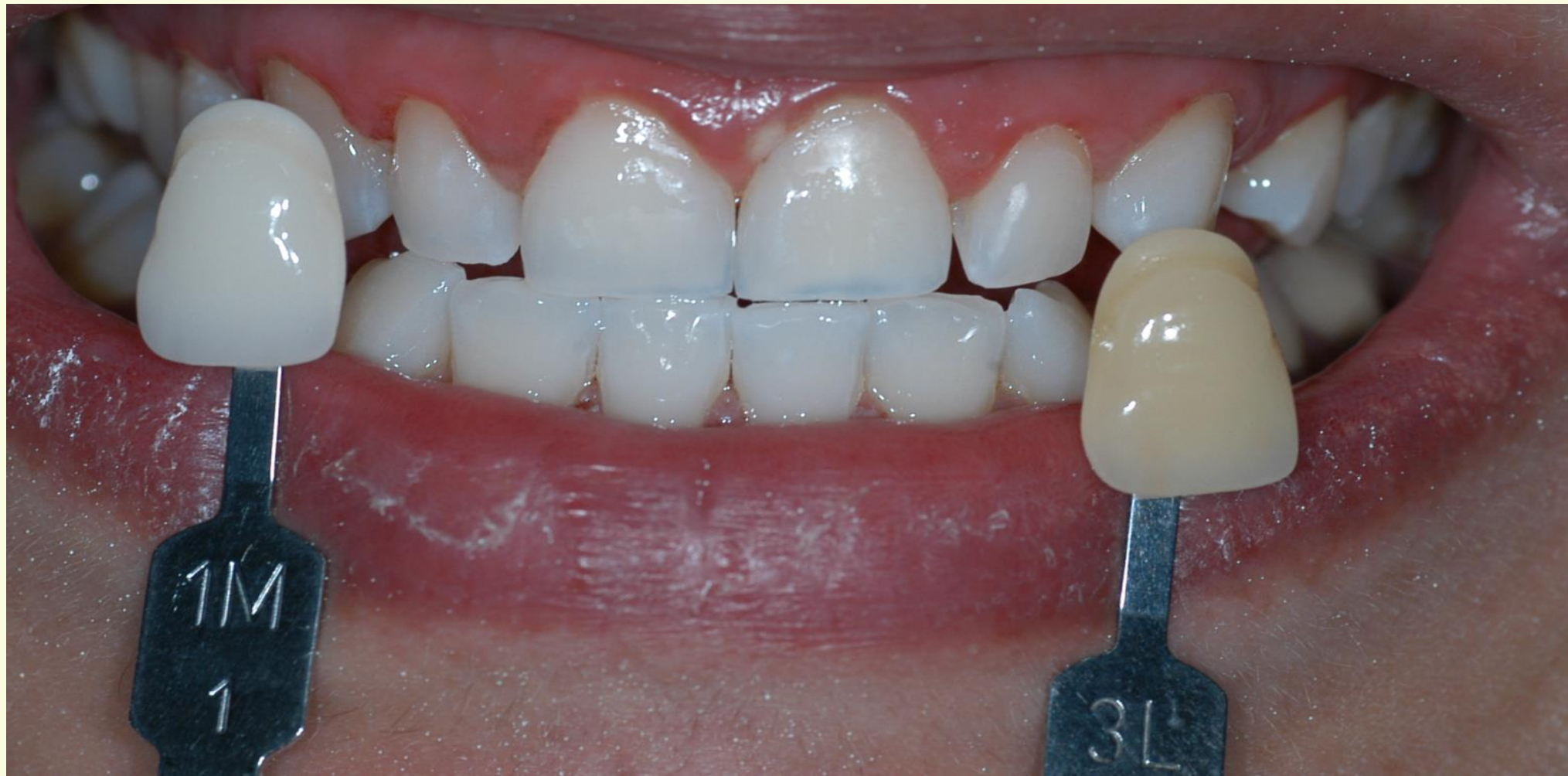



Apply Vitamin E Oil
To Sensitive Gingival Areas







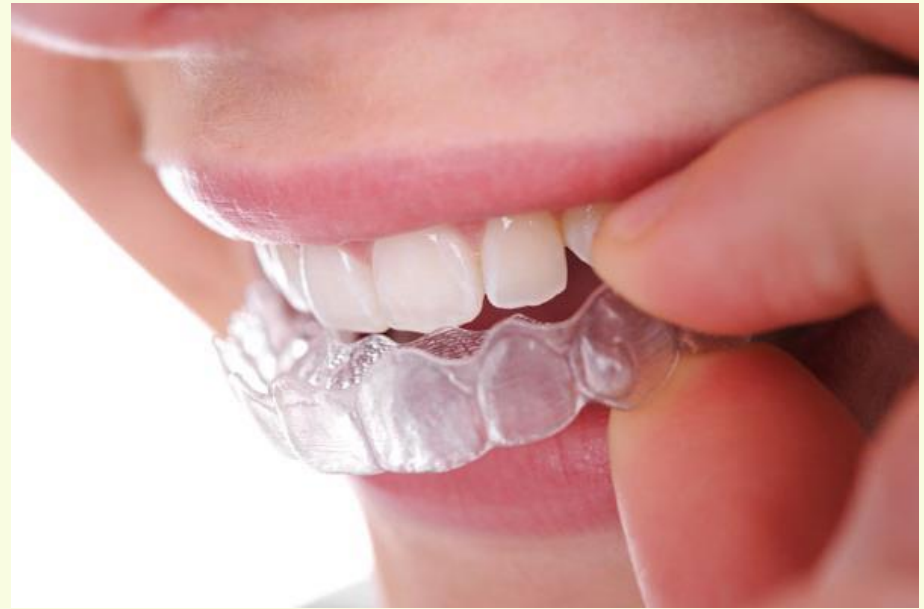
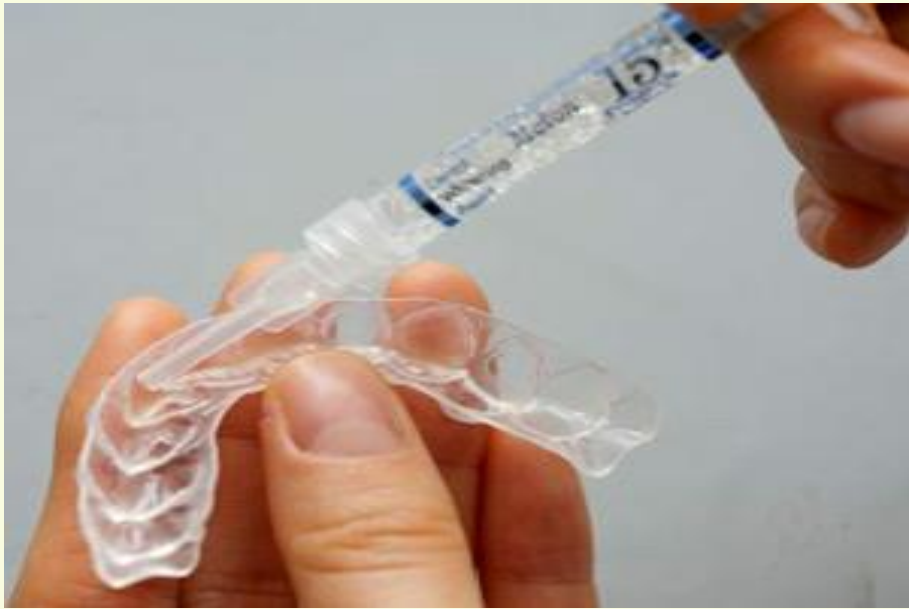
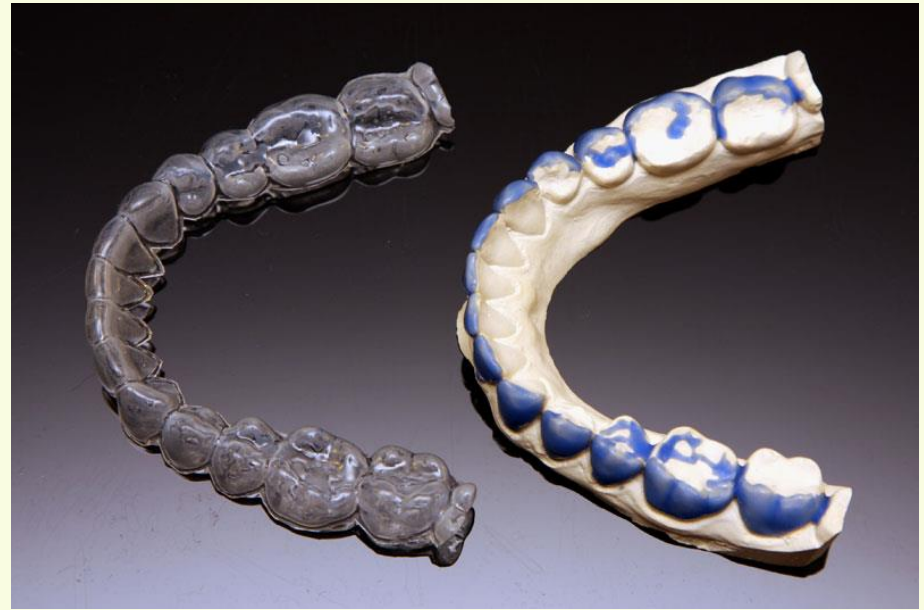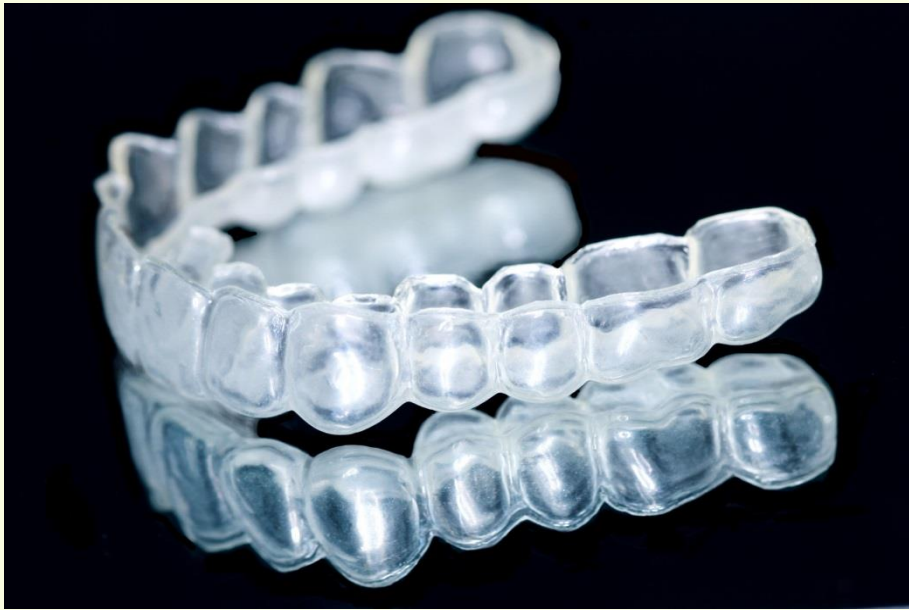ii- Dentist-provided (at-home) bleaching:

- In dentist-supervised or dentist-provided bleaching, an impression of the patient's teeth is taken and a custom tray is fabricated.
- The appliance should be well contoured at the gingival margins to reduce the potential for irritation and spaced over the teeth that are to be bleached.
- The whitening material is usually delivered as a viscous gel of 10- 20% Carbamide peroxide.



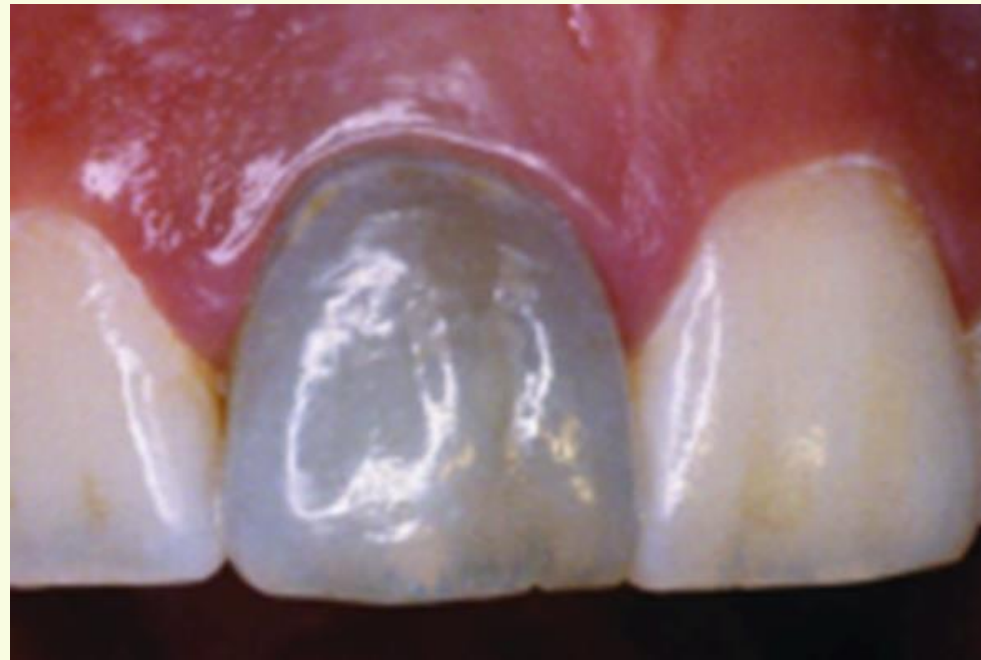- Home bleaching products are most successful if the patient applies the material into the trays for 6-8 hours a day (often overnight) and usually over a period of 3-4 weeks, but different products vary.
- For more intense stains, such as that found with tetracycline, it may take between 3 and 6 months to reach to a successful result.





IV.d.2: Non vital (internal) bleaching:

Main indication: to lighten teeth which have undergone root canal therapy.





Causes of internal discoloration:

- 1) Bleeding into dentine from trauma: dissemination of blood into the dentinal tubules. Iron is released during haemolysis and converted to black ferric sulphide causing grey staining of the tooth
- 2) Degradation of pulp tissue: Degrading proteins may cause discolouration. If the access cavity is prepared inappropriately, remaining pulp tissue cause discoloration after root canal treatment.
- 3) Staining from root canal filling materials: remnants of root-filling materials or medicaments are left in the pulp chamber and the staining substance infiltrates the dentinal tubules.



Non vital (internal) bleaching:

- Since the 1960s, hydrogen peroxide alone or with sodium perborate.
- The various techniques are based on a common action mechanism: the bleaching agent releases active oxygen inside the pulp chamber, from where it diffuses into the dentinal tubules. It oxidizes and bleaches the iron sulfide and other pigments present in the dentinal tubules.



Internal bleaching techniques:

- i. Walking Technique.
- ii. Thermocatalytic Technique.
- iii. Combined Technique.
- iv. The 'inside/outside' technique



i- Walking bleaching:

- It was first introduced in 1961 by Spasser.
- A mixture of sodium perborate and water is placed inside the pulp chamber, sealed in place and left to act for 5 to 7 days.
- The mixture is renewed weekly until the desired result has been achieved



Clinical steps for walking bleaching:

Preliminary treatment:

- 1) The tooth surface should be cleaned thoroughly to estimate the degree of discolouration.
- 2) The patient should be informed that the results of bleaching therapies are not always predictable and that complete recovery of colour is not guaranteed in all cases



3) Examination of root fillings, existing restorations and tooth substance:

- a) Prior to treatment, a radiograph should be taken to check the quality of the root filling.
- b) Deficient tooth fillings have be restored, unsatisfactory root canal treatment have to be treated and caries has to be removed and a filling placed.



4) Preparation of pulp cavity:

a- Rubber dam applied.

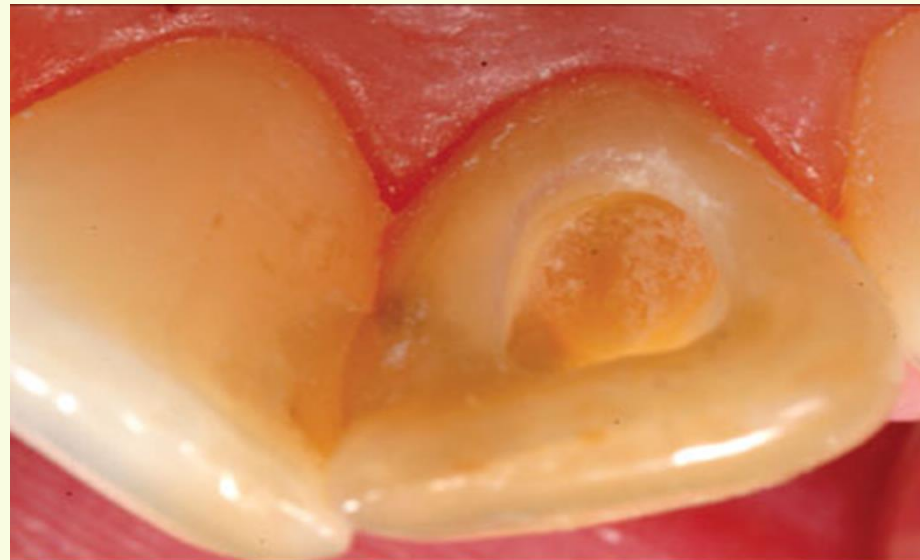
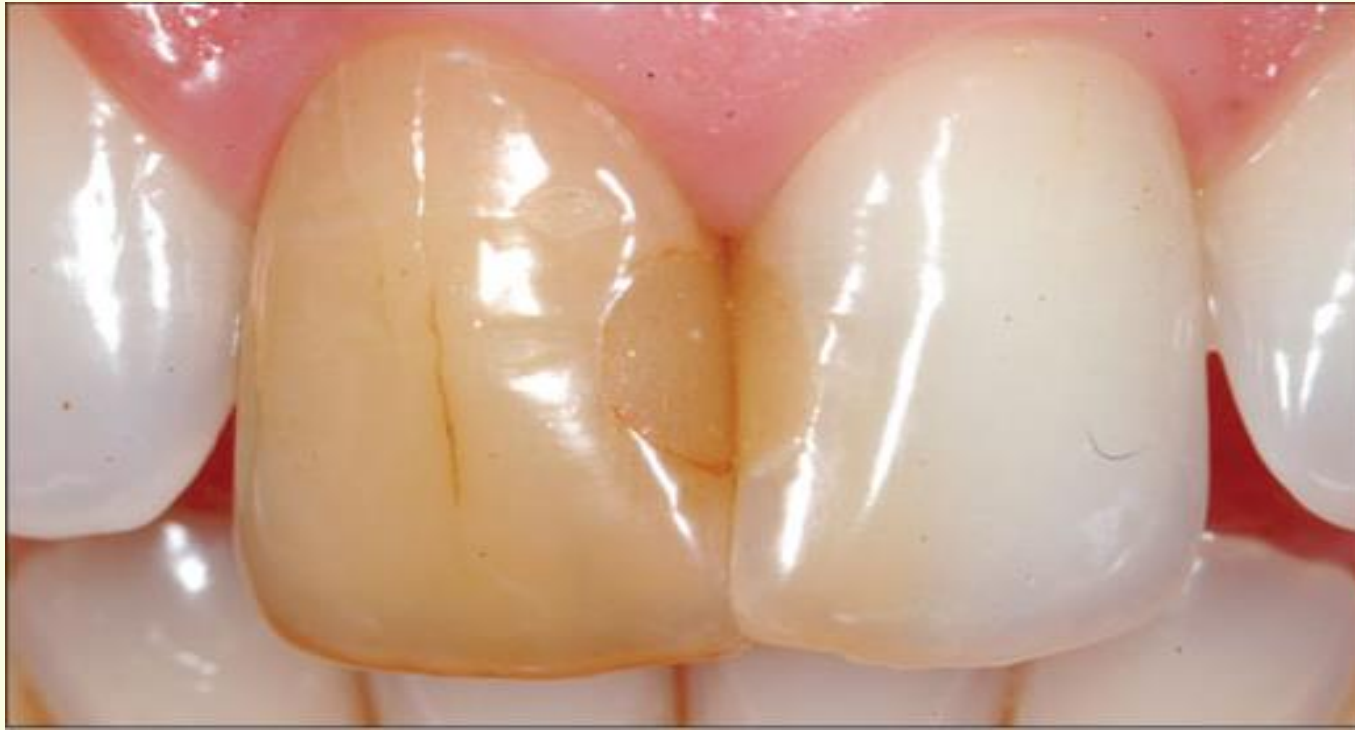b- Restorative materials, root canal filling material and remnant pulp tissue removed.

c- Washing of the cavity with NaOCl.

d- Cervical seal:

1) Root filling should be reduced 1-2mm below cemento-enamel junction.

2) A 2-3mm GIC layer is placed to seal the root canal.



Tooth was root canal treated and a 2mm glass ionomer seal applied

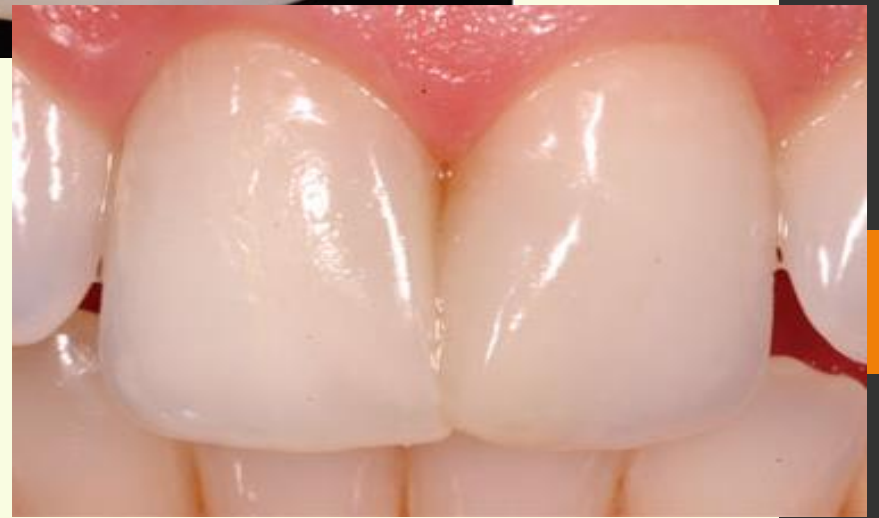
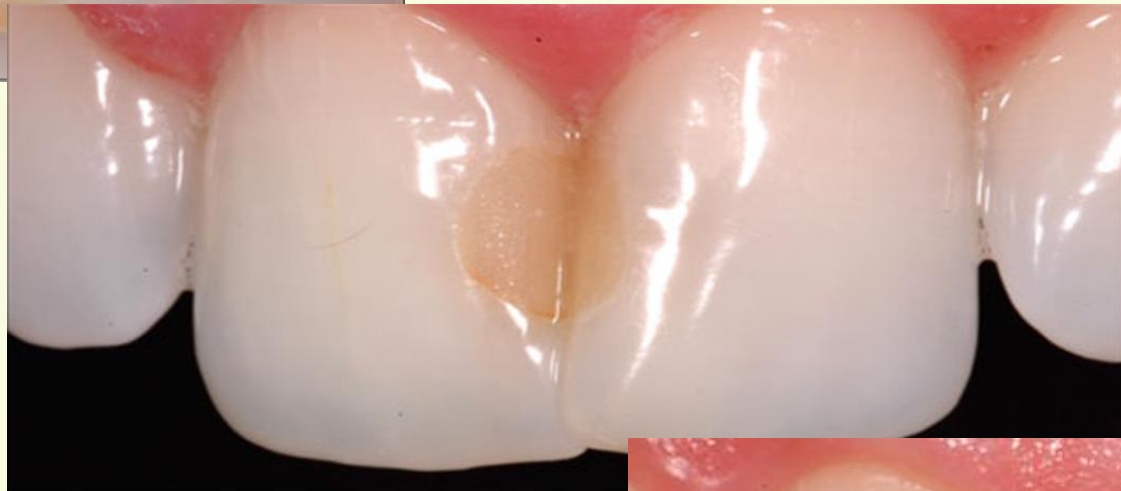
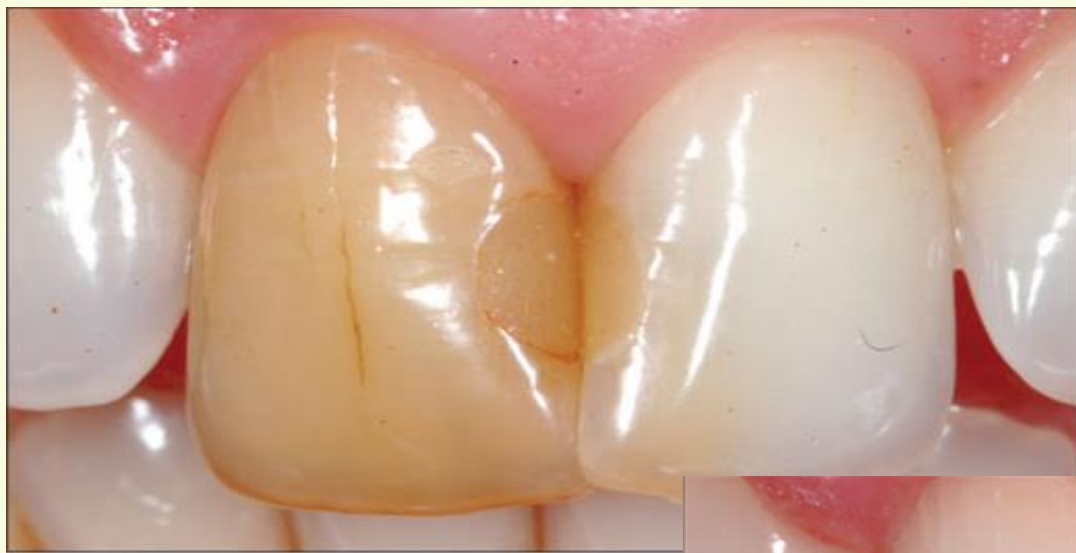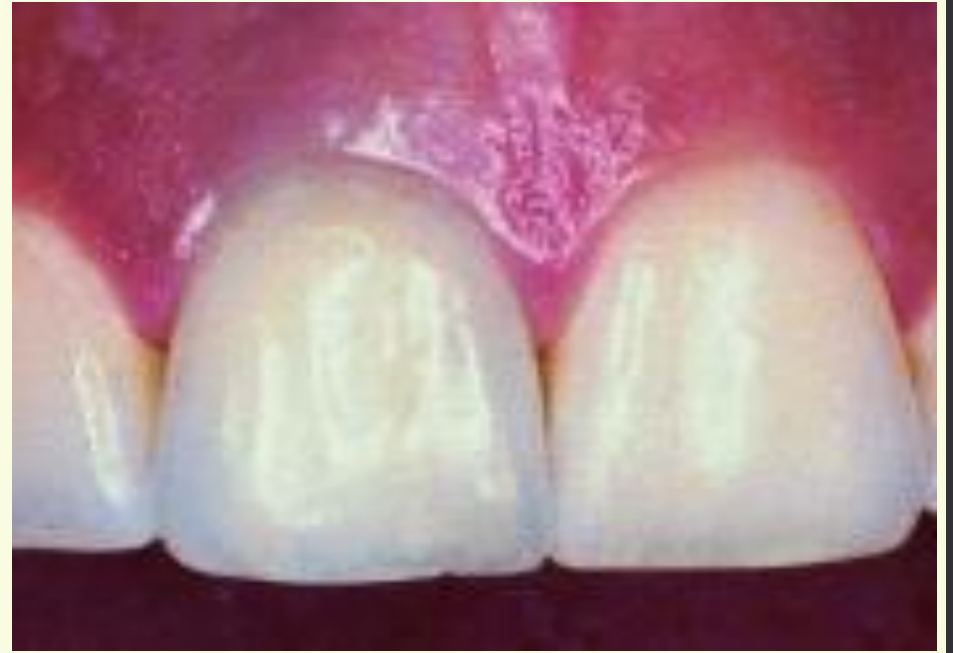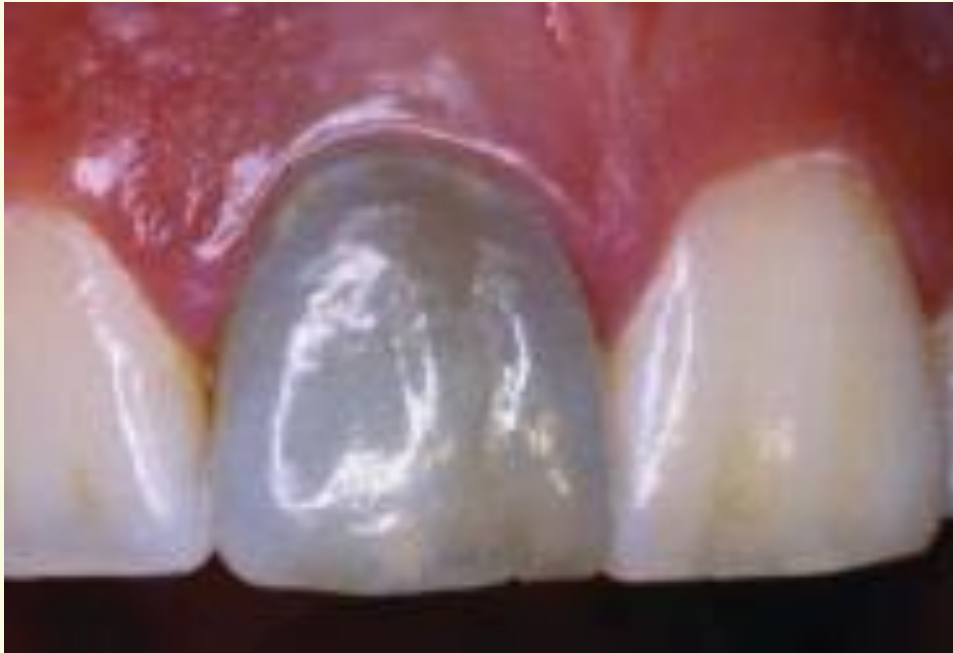5) Application of the bleaching agent:

- a- Sodium perborate is mixed with distilled water in a ratio of 2 :1 and placed in the tooth cavity. H_2O_2 can be used instead of water in severe discolourations.
- b- A cotton pellet is placed into the tooth cavity.
- c- A sound seal of the access cavity with composite or compomer restorative is done to avoid leakage of the bleaching agent into the oral cavity.



- Patients should be instructed to evaluate the tooth colour on a daily basis.
- Patient should attend the clinic every week for application of a fresh mix of the bleaching material and for evaluation of the degree of tooth whitening.
- Patient should return when the tooth whitening is acceptable in order to avoid over-bleaching.
- Following bleaching, the access cavity should be restored with a permanent composite filling.
- Follow up radiographs should be taken to rule out cervical resorption.







ii- Thermocatalytic bleaching

- Introduced by Stewart in 1965.
- 30-35% H_2O_2 is applied to the pulp cavity and a heated instrument or UV light is used to activate the bleaching agent to increase its efficacy.
- The treatment is repeated twice or more, for a number of sessions until the desired esthetic result has been achieved.



iii- Combined bleaching

- A combination of the thermocatalytic and walking techniques.
- Root canal is sealed, the bleaching material is placed into the pulp chamber and a heated instrument is used to activate it.

Then tooth is sealed with bleaching material inside.



iv- 'inside/outside' bleaching technique:

- A customized tray with reservoirs on the labial and palatal surfaces of the non-vital target tooth.
- The root canal is sealed and the pulp chamber is left open and completely covered by 10% carbamide peroxide within the tray.
- The gel is changed every two hours and the patient is advised to wear the tray continuously, including night-time wear. Bleaching usually occurs within 2–3 days.



IV.e- Potential Adverse effects:

- 1- Sensitivity.
- 2- Shade regression
- 3- Gingival irritation
- 4- Cervical resorption
- 5- Tooth tissue changes
- 6- Cancer risk
- 7- Effect on pulp



1- Sensitivity

- 15 to 65% of patients reported increased tooth sensitivity when 10% carbamide peroxide was used.
- Higher incidence of tooth sensitivity (from 67 to 78%) was reported after in-office bleaching with hydrogen peroxide in combination with heat.
- Temporary. Normally persists for up to 4 days after the cessation of bleaching treatment, but a longer duration of up to 39 days has been reported.
- Can be reduced by: ceasing treatment, use of lower concentration agents, reduced frequency, use of fluoride and desensitizing agents (eg: Gluma).



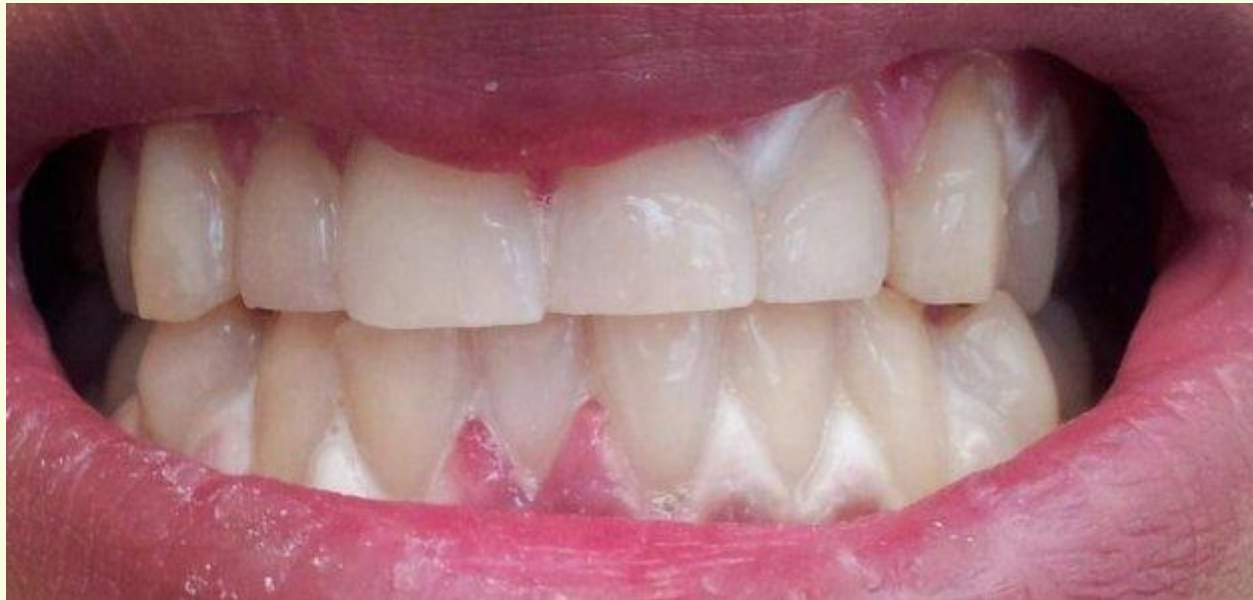2- Shade regression:

- Slight regression occurs usually within the first 2 weeks.
- Definitive restoration placement should be delayed by at least 2 weeks.
- This also allows the diffusion of any residual free radicals that may interfere with bonding and polymerization.
- 20% of bleached teeth get discoloured again in 3 year depending on oral hygiene and diet.



3- Gingival irritation:

- A high concentration of hydrogen peroxide is caustic to mucous membranes and may cause burns and bleaching of the gingiva.





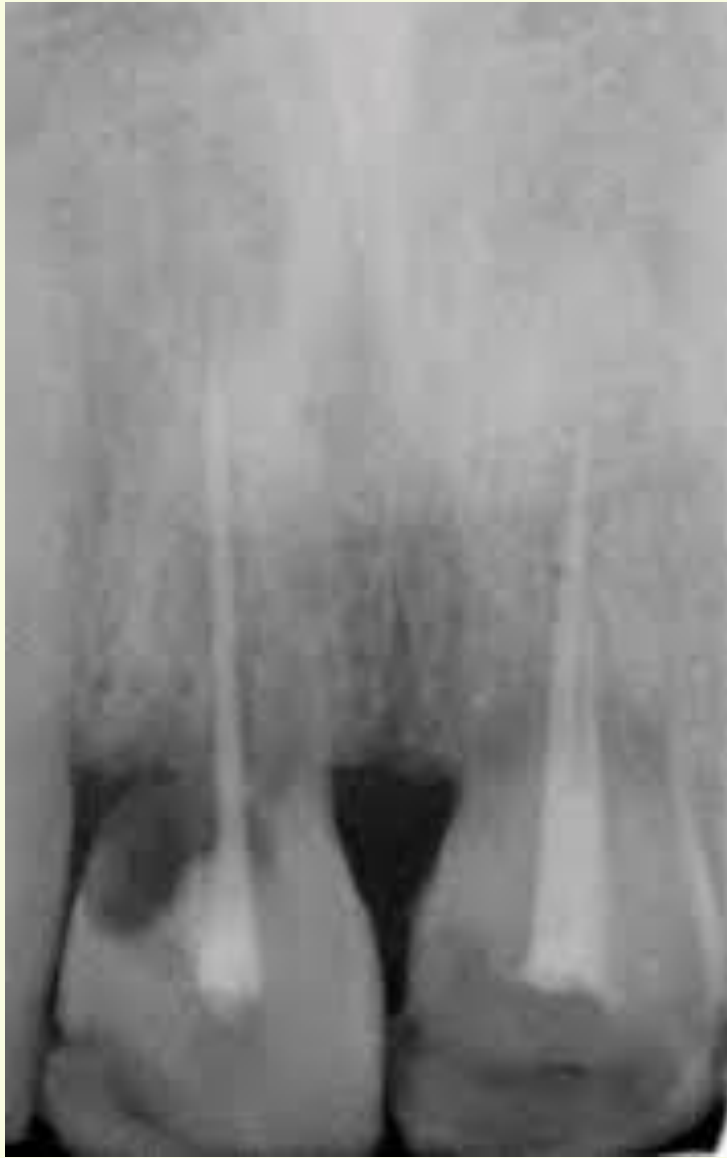4- Cervical resorption:

Possible mechanisms:

- Inflammatory reaction due to leakage of bleaching material to gingival tissues.
- pH lowered to a level that stimulates osteoclasts.
- Structural changes to dentine (denaturation of proteins)

Risk increases with:

- Internal bleaching (no reported cases with external bleaching)
- High concentration (30% H₂O₂)
- Defective/ absence of cervical barrier
- The use of heat (thermocatalytic technique)





5- Tooth tissue changes:

- Decreased micro-hardness
- Minimal effects. Insignificant clinically.

6- Cancer risk:

- H₂O₂ has been linked with mutagenic changes.
- In bleaching: low concen. + short application time.
- No evidence of risk.



7- Effect on pulp:

- Concerns about the potential for pulpal irritation during vital pulp bleaching have arisen due to the long duration that the chemicals are in contact with teeth, particularly if dentine with open tubules or cracks are present.
- A clinical trial showed that vital bleaching with 10% carbamide peroxide in a custom tray for 6 weeks were safe for the pulp health up to 10 years postoperatively (*Ritter et al., 2002*)



IV.f- Clinical considerations:

- Remnants of peroxide or oxygen in the tooth inhibit the polymerization of composite. No loss of bond strength is noted if the composite restorative treatment is delayed at least one week after the cessation of any bleaching procedure.
- Certain metallic ions (mercury, silver, copper and iodine) are extremely difficult to remove or alter by bleaching.



Factors affecting efficacy of bleaching

- Age of patient.
- Bleaching material and technique used.
- Strength of bleaching agent.
- Aetiology and severity of tooth discoloration.
- Patient compliance.
- Light and heat activation.



Other treatment options: Acid Abrasion

- Hydrochloric acid (18%) used together with the pumice to remove the outer portion of stained enamel (50- 200 μm).
- Simultaneous actions of erosion and abrasion.
- It is limited to localized discoloration and is not applicable to more extensive stains such as tetracycline and age-related changes.



Laser tooth bleaching

- Laser bleaching started in 1996 with approval of argon and carbon dioxide lasers by the FDA. There are only a few *in vitro* studies on the efficacy of laser bleaching.



Bleaching strips

- First introduced in 2000 to the US market.
- Flexible, impregnated, polyethylene bleaching strips are designed to deliver hydrogen peroxide in various concentrations: 6%, 6.5%, 10% and 14%.
- They are applied in an adhesive gel form to the labial surface of anterior teeth. Might cause gingival injury



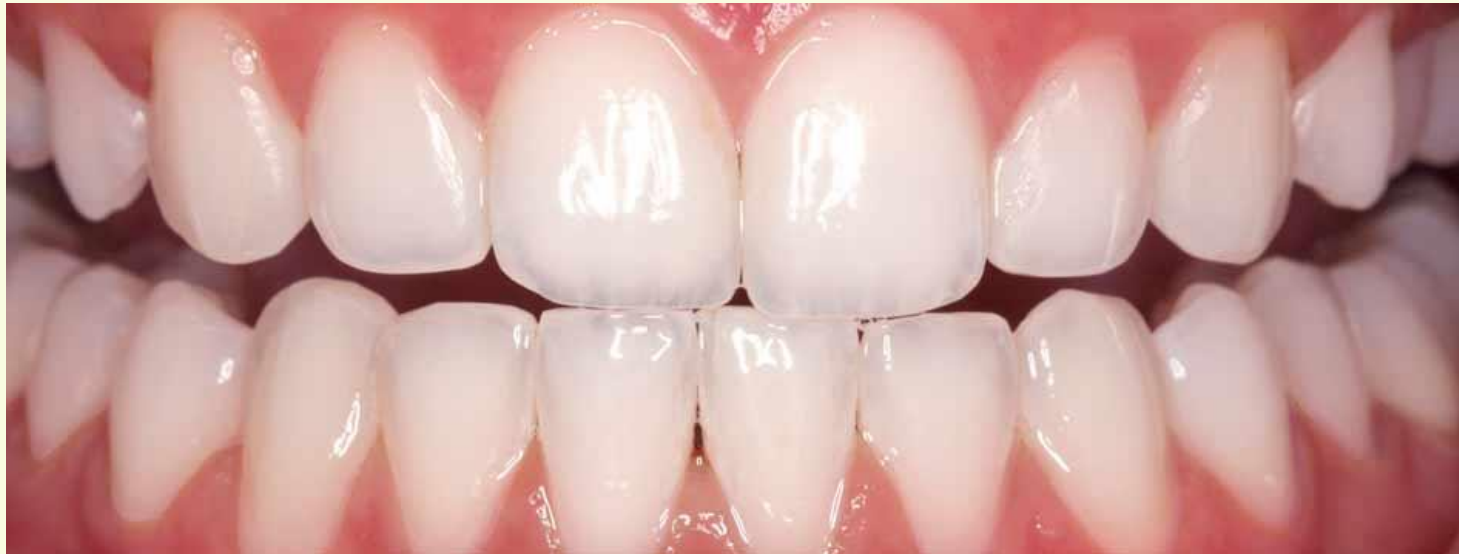
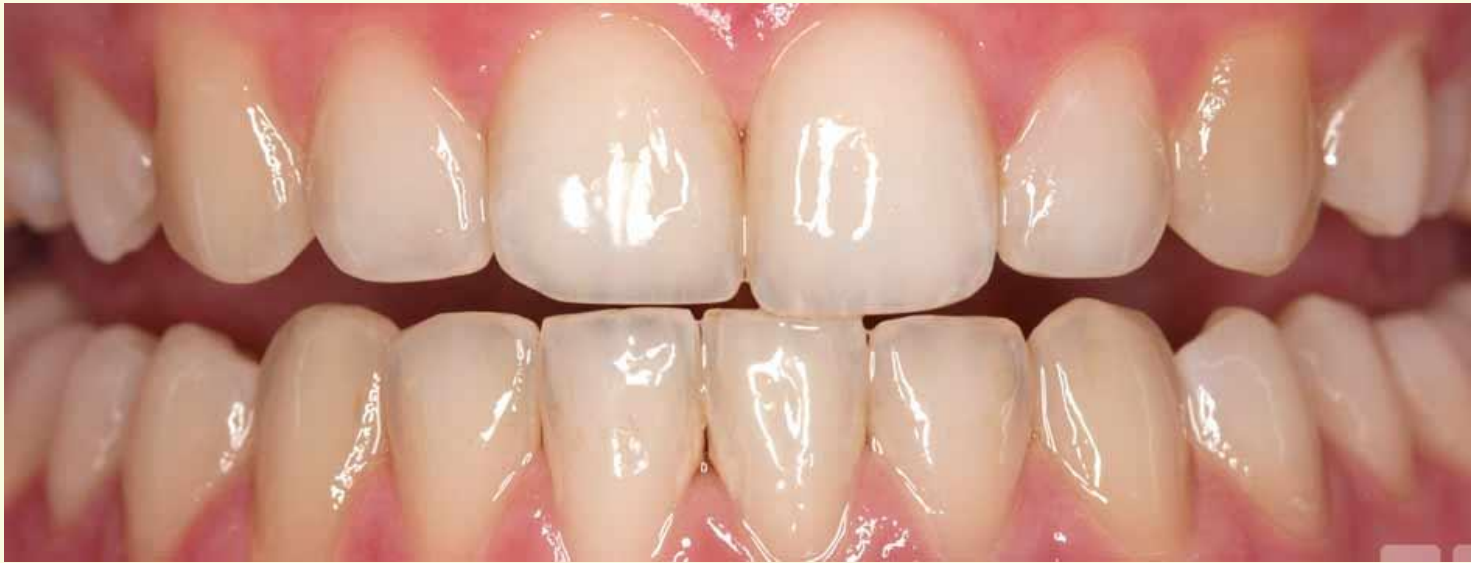
Paint-on gel

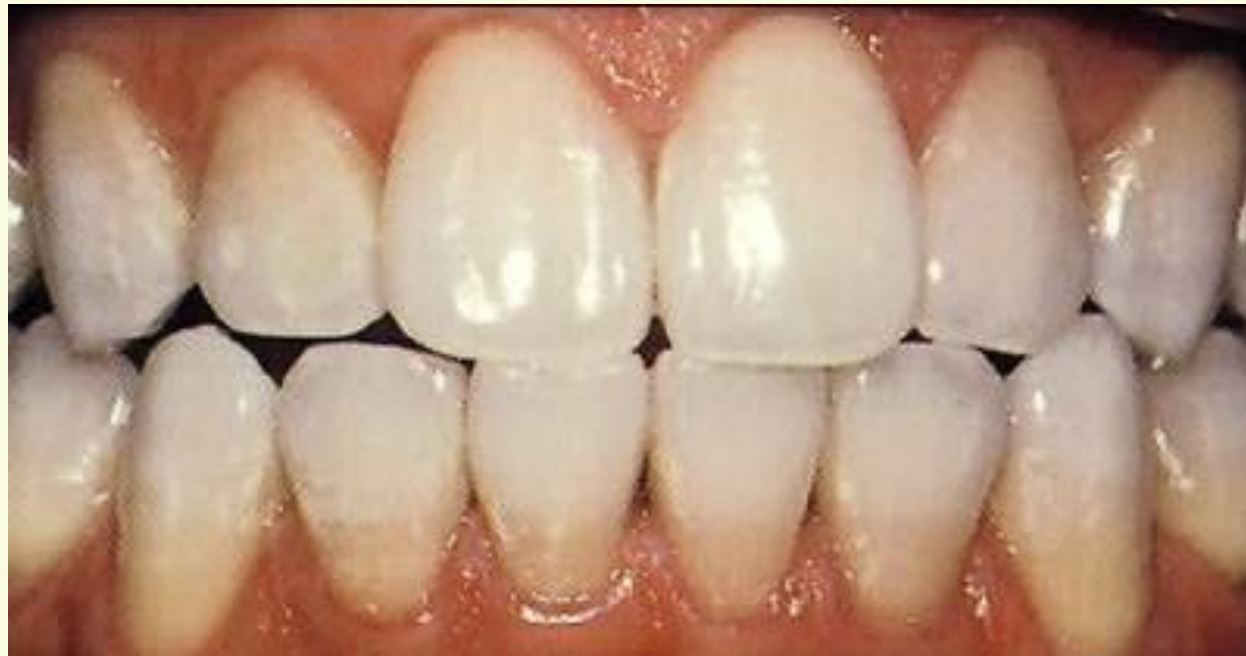
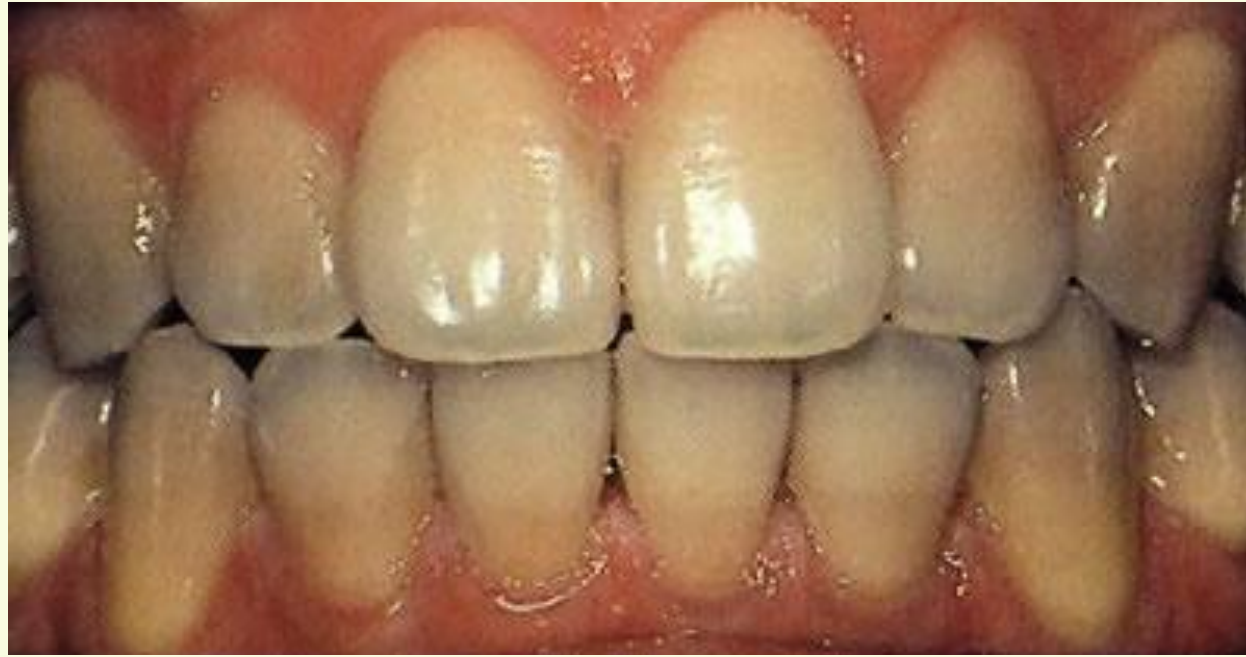- In 2004, a topically applied tooth bleaching system, in the form of a paint-on gel, was marketed in the USA.
- It would have a more widespread cosmetic appeal, as it would be capable of being applied to individual problem teeth, avoid the need for trays and develop a range of bleaching systems that would be entirely over-the-counter (OTC).

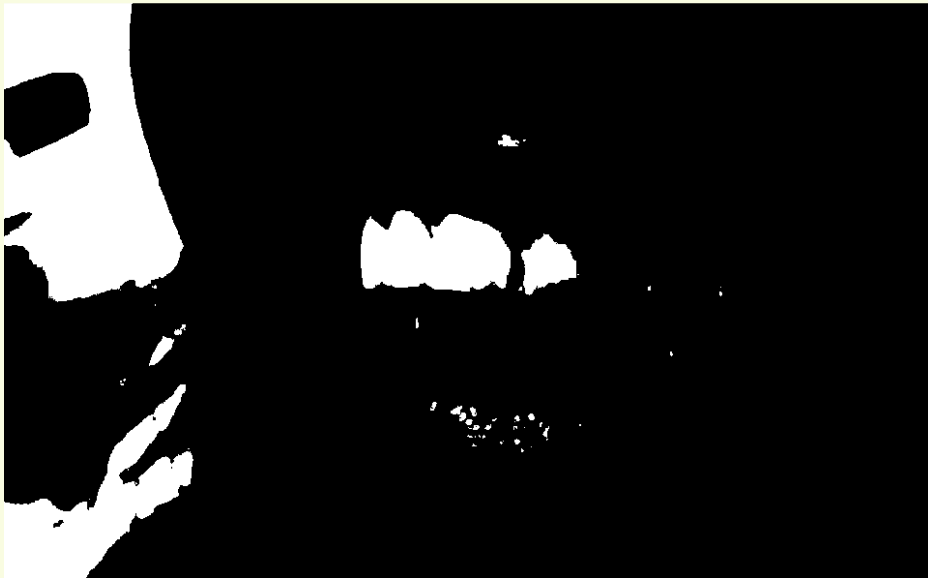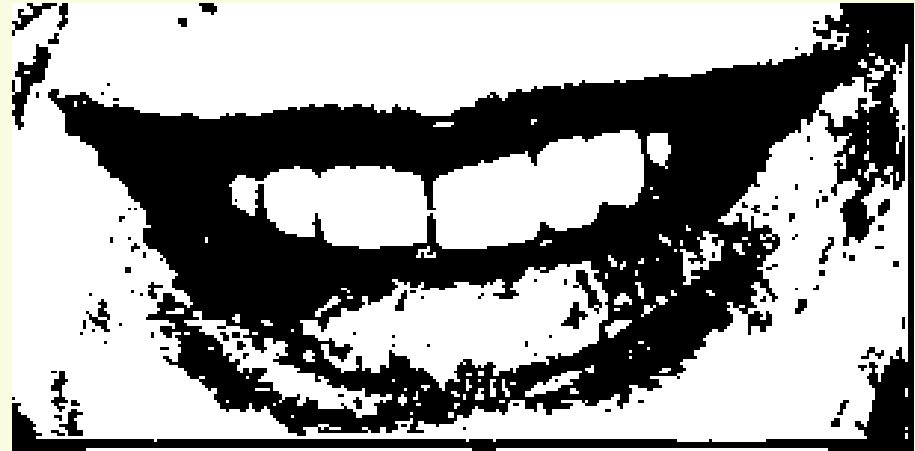
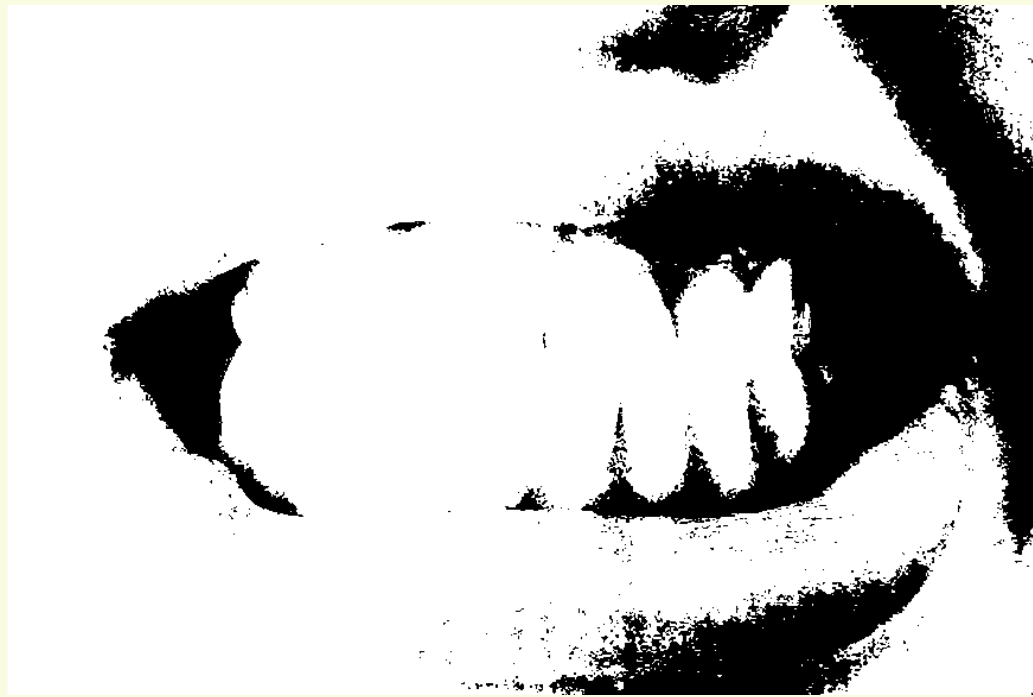




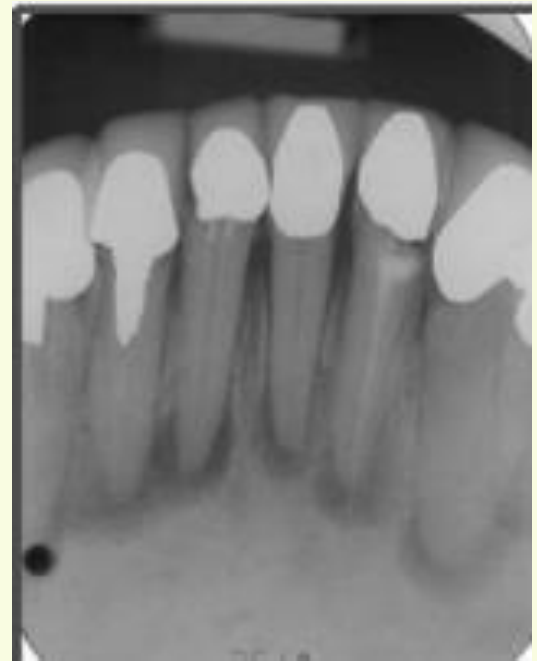
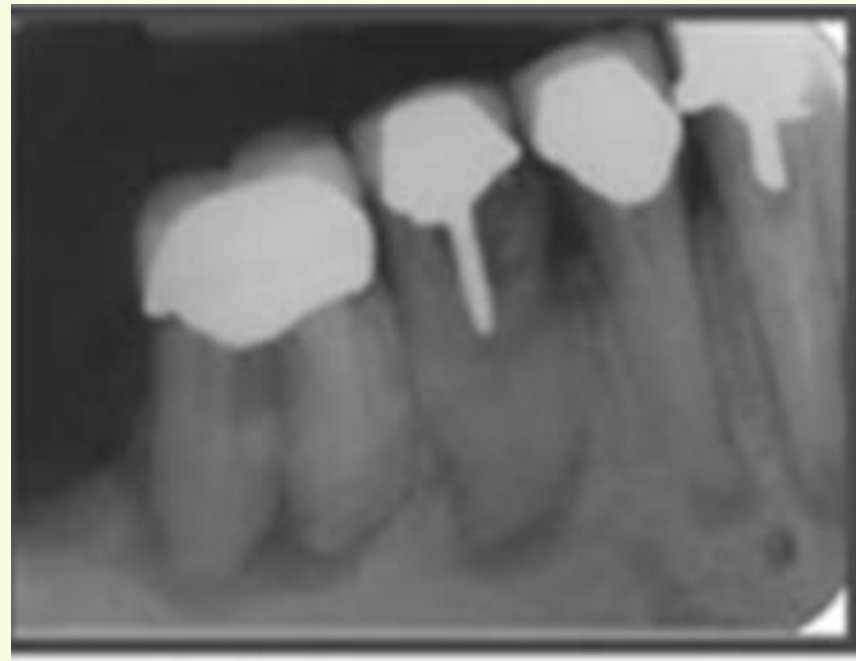

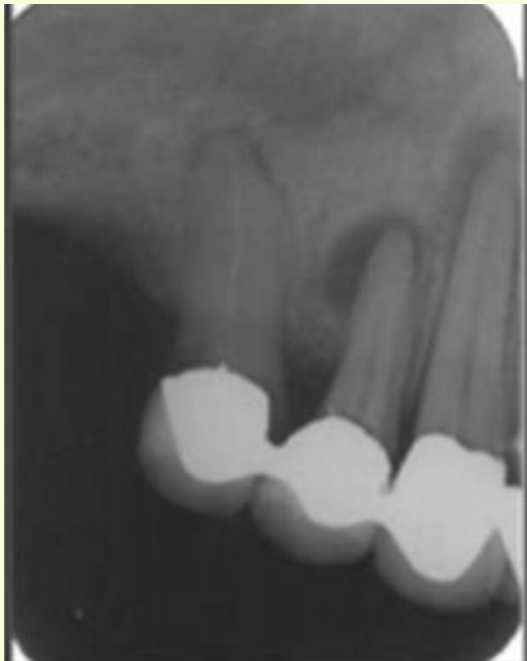
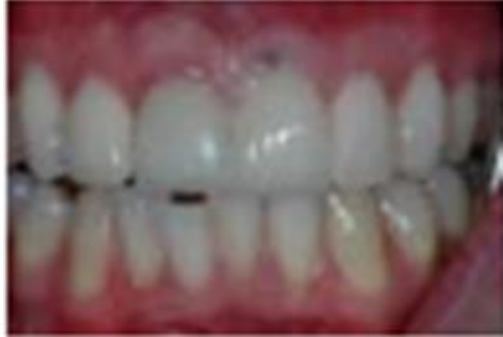
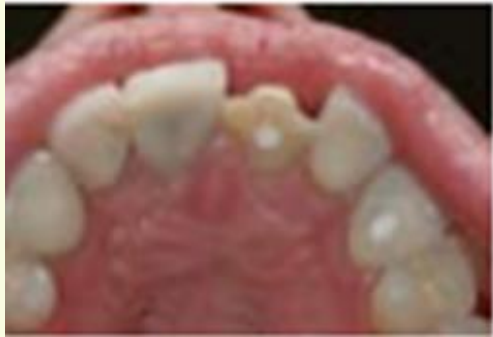
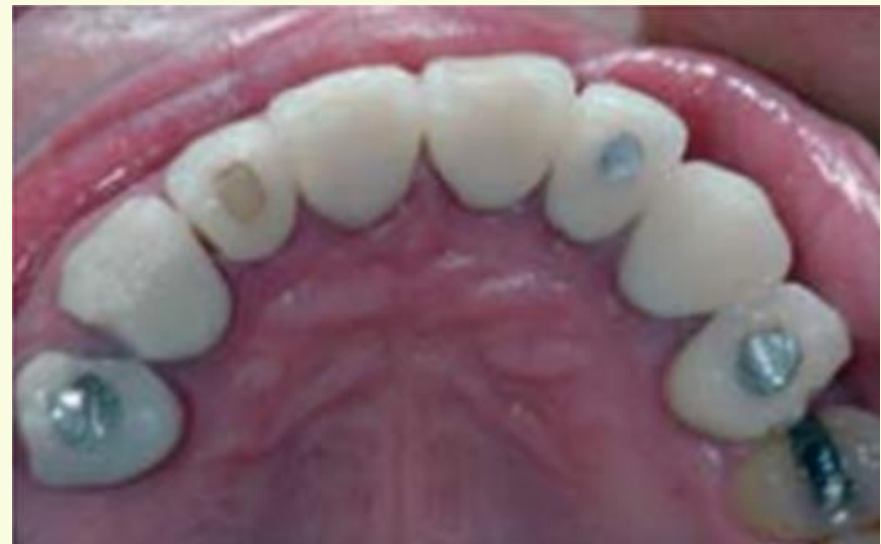
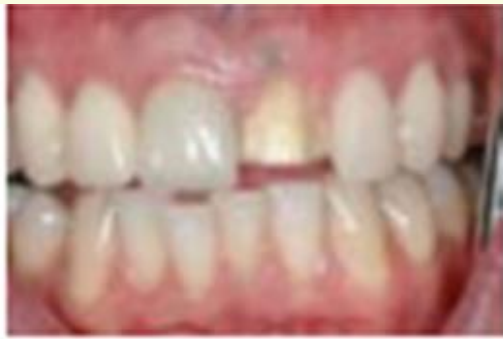
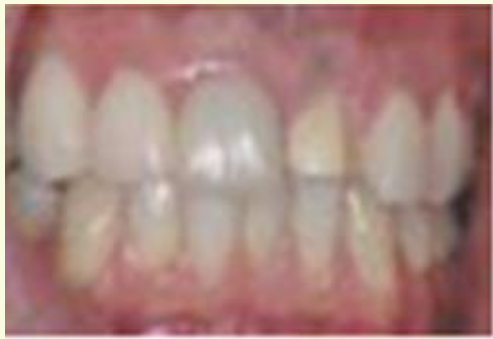








Martin G D Kelleher

The 'Daughter Test' in Aesthetic ('Esthetic') or Cosmetic Dentistry

'Knowing what I know about what is involved with this proposed dentistry would I carry out this treatment on my own daughter's teeth?'



THANK YOU